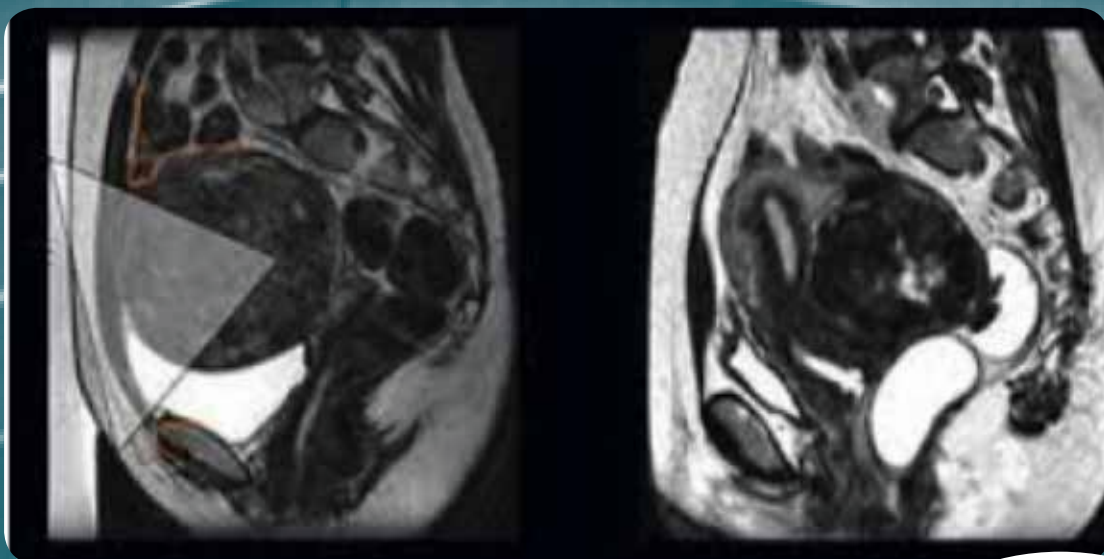
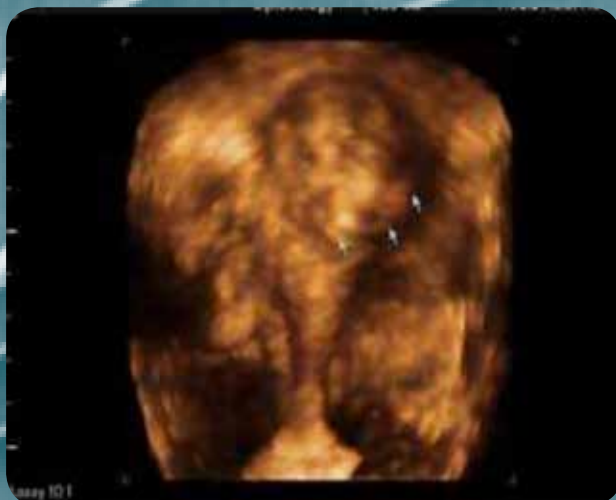

# ARText : 6



**Sixth Issue**  
Volume No : VI /Mar 2018

## Fibroids & Infertility



Editor :  
**Prof (Dr) Pankaj Talwar**

An initiative by  
**Gynova**  
MAKES DREAM COME TRUE



# ARText

Fibroids & Infertility





**Dr Gouri Devi**

**PRESIDENT-IFS**

It is a great privilege for me to pen down this message for the Sixth E-bulletin of IFS-ARTeXt on the subject of "Fibroids and infertility". Fibroids play a more controversial role than previously thought in determining whether the embryo will implant or not. This common challenge in ART practice needs to be further simplified and understood.

With this new edition of the ARTeXt, We have tried to answer questions about the etiologies, symptoms and also discuss available strategies to improve the ART prognosis in women with myomas. I am sure this bulletin will immensely benefit you all.

Team ARTeXt sincerely hopes to bring out such teaching material for you regularly in future too. It would not only help to disseminate scientific and ethical subject related content but also constantly update everyone with new researches and developments across the world.

We would also like to place record our truthful thanks to Cadila Healthcare Ltd, for helping us in this publication and off course I promise that there is no conflict of interest at any level.

Wish you a happy reading and yes don't forget to file this issue.

**Dr Pankaj Talwar**

**SECRETARY GENERAL IFS**

**Editor - ARTeXt**

This is an honour for me to write best wishes message for this E-bulletin of IFS-ARTeXt. We have always believed in spreading awareness about the common issues in ART and tried to gather and present the evidence that will undoubtedly help both the clinicians and the patients. We intend to cover common day-to-day challenges in clinical ART and thus we bring out E-bulletin named ARTeXt every month. The aim is to simplify the complex issues in clinical ART and present before you in concise manner. I am sure that you would appreciate and learn from this academic pursuit of the IFS. In this issue we would be covering "fibroids" which is still an enigma. This manual may help you find the required answers for the queries related to this topic.

The bulletin is penned in three parts. Part 1 deals with the basics of fibroids. Part 2 deals with the frequently asked questions debatable issues concerning ART and the disease and Part 3 would cover at length the current guidelines and recommendations pertaining to myomas and infertility.





**Dr Tanya Buckshee Rohatgi**  
**Co-Editor**

**MD DNB MNAMS FICOG (N Delhi)**

**MRCOG (London, UK) Diploma in Reproductive and Sexual Health (London, UK)**

**MSc (Distinction) Consultant in Reproduction and IVF (Bristol, UK)**

**Consultant Training in Obstetrics & Gynaecology (Leeds Teaching Hospitals, NHS, UK)**

**Fellowship in Onco-Fertility and PGD (KK IVF Singapore & Chelsea & Westminster Hospital London)**

**Senior Consultant in Reproductive Medicine & Onco-Fertility Max Hospitals, New Delhi**

Fibroids are the most common reproductive tract tumors that can present major quality of life problems for a large fraction of women. Controversies still perplex patients and clinicians dealing with fibroids and subfertility, especially its impact on ART outcomes.

This comprehensive review aims to explore all aspects of fibroids ranging from etio-pathogenesis to controversies in its clinical impact on fertility along with a bird's eye view of all treatment options.

We hope you all have an enjoyable read.

## Index

Sr No	Topic	PageNo
<b>Part - 1 Understanding Fibroids</b>		
I	Introduction	7
II	Pathogenesis	7
III	Aetiology	7
IV	Risk factors	9
V	Classification	11
VI	Symptoms	12
VII	Diagnosis	13
VIII	Differential Diagnosis	16
IX	Treatment	17
<b>Part - 2 Frequently Asked Questions</b>		
I	What potential mechanisms are involved in small intra mural fibroids affecting fertility?	24
II	What type of fibroids affect fertility ?	24
III	What is impact of small non-cavity distorting intramural fibroids on ART ?	24
IV	Is myomectomy recommended before IVF for non-cavity distorting intramural fibroids ?	25
V	What complications can occur in pregnancy due to fibroids ?	25
VI	What is the role of Ulipristal in management of fibroids ?	25
VII	What are the endometrial changes associated with PRM agents ?	26
VIII	Is there a new oral antagonist that can be used for treatment of fibroids instead of the injection ?	26
IX	Are there any potential disadvantages of pre-operative GnRh agonist use especially when myomectomy is planned ?	26
X	What is the STEP-W submucosal fibroid classification system?	27
XI	What is the current opinion regarding power morcellation ?	27
<b>Part - 3 International Guidelines</b>		
XII	International Guidelines	33



The background is a solid teal color with a subtle, high-magnification microscopic image of cells, possibly fibroblasts, overlaid. The cells are small, rounded, and have a granular texture, distributed across the entire frame.

# Part - 1

## Fibroids & Infertility

## Introduction

**Uterine leiomyomas (ULs)**, or uterine fibroids, are the **most common reproductive tract tumor** in women that are steroid hormone responsive, benign monoclonal tumours of the smooth muscle compartment (myometrium) of the uterus.

Although found elsewhere in the body, leiomyomas most frequently occur in the myometrium. Uterine leiomyomas are commonly referred to as myomas, fibromyomas, or “fibroids” because of their firm, fibrous character and high content of collagen.

It is estimated that up to **77% of all women will develop UL in their lifetime** and 15 to 30% of these women suffer from substantial symptoms, including pelvic discomfort, dysmenorrhea, menorrhagia, anemia, urinary incontinence, recurrent pregnancy loss, preterm labor, and in some cases infertility. **(McWilliams MM et al)**

## Pathogenesis

At least two distinct components contribute to leiomyoma development:

- Transformation of normal myocytes into abnormal myocytes, in most instances through somatic mutations
- Growth of abnormal myocytes into clinically apparent tumours

The first process appears to be quite common, in view of the high prevalence of microscopic myomas. **Myometrial and leiomyoma stem cells** have been identified that transform and grow into leiomyomas under the influence of hormones.

**(Cramer et al 1990, Hashimoto et al 1995)**

## Aetiology

### Steroid Hormones

It is believed that sex steroids promote development of leiomyomas by stimulating inappropriate expression of growth factors. **Estrogen and progesterone** act as physiologic regulators of gene expression by activating nuclear receptors that are themselves transcription factors. In this way estrogen and progesterone play a key role in regulating genes that direct cell growth.

Assay for estrogen and progesterone receptors in myomas show the concentration to be about ten times the concentration in normal myometrium. Local uterine tissue concentrations of hormones and hormone receptors differ between UL and healthy myometrial tissue. **ULs have higher concentrations of estradiol, aromatase, progesterone receptor (PR), and estrogen receptor- $\alpha$  (ER- $\alpha$ ).** Increased expression of ER- $\alpha$  and PR is independent of tumour size, can be heterogeneous within tumours of one patient, and is consistent throughout all the menstrual cycle phases. **(Stewart et al 2001, Parker et al 2007)**

However, it is **progesterone that influences the proliferation of leiomyoma far more** than estrogen. a strong support for progesterone involvement in UL growth comes from anti-progestin therapies. The **anti-progestine drugs**, such as RU-486, Proellex (CDB4124), Ulipristal acetate (CDB2914), and Mifepristone, cause regression of UL tumor size and symptoms as well as a decrease in ECM formation in UL. The selective PR modulator, Asoprisnil, is also used as a short-term effective treatment for UL tumor symptoms and size. **(Kim JJ et al 2013)**

**Low circulating 25-hydroxyvitamin D** among **African American women** has been associated with higher incidence of UL. Hence, supplementation of vitamin D3 has been suggested as a potential long-term therapeutic option for UL prevention and treatment **(Baird et al 2013)**



## Cytogenetic Karyotypic Abnormalities

Karyotypic abnormalities occur in 40 to 50% of ULs, and tumors from the same uterus often show different chromosomal changes. The **most common abnormalities are translocations on chromosome 12; deletion on chromosomes 3q and 7q; trisomy 12; and rearrangements on chromosomes 6, 10, and 13.** (Bulun SE et al 2010)

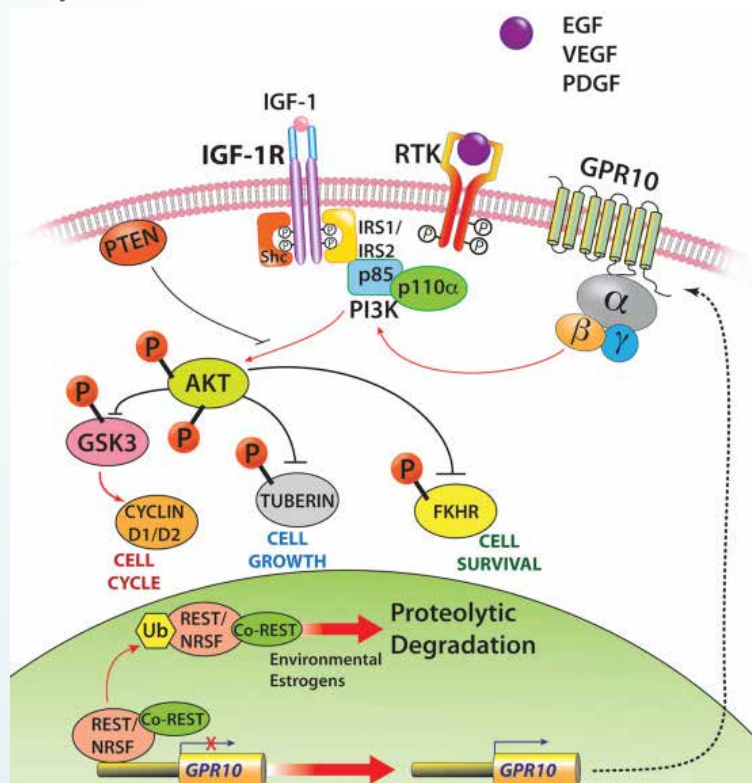
Recently, research on a **somatic mutation (c.131G > A)** in the mediator complex subunit 12 (**MED12**) has gained attention, as this is an important contributor to UL etiology. Mutations in exon 2 of MED12 are present specifically in approximately 70% of ULs, and not in surrounding myometrial tissue. (Mäkinen N et al 2011)

## Cell Signalling Pathways

The **PI3K/AKT-mTOR pathway** has been identified as one of the **most upregulated signaling pathways in UL**, based on evidence from protein and transcriptional profiling of human UL, as well as in the Eker rat animal model. In addition, there is evidence that PI3K and mTOR are necessary for estrogen dependent cell growth in UL and myometrial cell cultures. (Crabtree JS et al 2009)

Studies by Varghese et al indicated that the loss of tumor suppressor NRSF/REST and the ensuing expression of GPR10, a neuron-specific G-protein-coupled receptor, activates PI3K/AKT-mTOR pathway in UL (see Fig. 1). (Varghese BV et al 2013)

**Targeting of the PI3K/AKT-mTOR pathway as a potential future therapeutic option** for UL is currently being explored by some laboratories. **The AKT inhibitor, MK-2206, shows promise** in the laboratory in limiting UL growth and increasing cell death. However, side effects of rash, diarrhoea, fatigue, and mucositis in patients treated with MK-2206 are common due to the pervasive extent of AKT signalling in normal physiology. These side effects may limit the use of AKT inhibitor therapies for UL treatment. (Lara PN Jr et al 2015)



**Figure 1. Molecular pathways that promote uterine leiomyoma pathogenesis.** (Varghese BV et al 2013)



## Risk factors

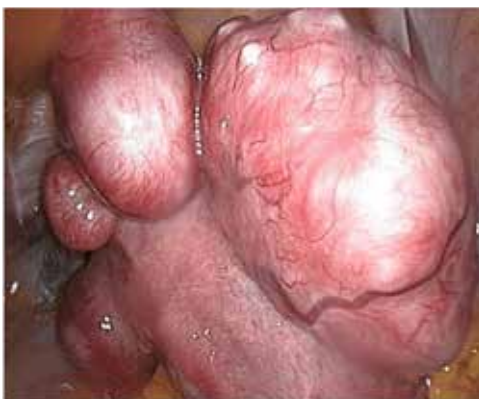Vikhlyaeva and colleagues reported that fibroids were **2.2 times more frequent in first-degree** relatives within families in which there were two or more family members with fibroids. (Vikhlyaeva et al 1995)

**Table 1: Factors that affect the risk of fibroids**

<i>Decreased Risk</i>	<i>Increased Risk</i>
<ul style="list-style-type: none"> <li>• Increased Parity</li> <li>• Late Menarche (&gt;16yrs)</li> <li>• Long -acting progestin only pills</li> <li>• Green vegetables (0.5-fold decreased risk) and fruit (especially citrus fruit)</li> <li>• Smoking may decrease risk possibly through inhibition of aromatase</li> </ul>	<ul style="list-style-type: none"> <li>• African race</li> <li>• Age &gt; 40yrs</li> <li>• Nulliparous</li> <li>• Early menarche (&lt; 10yrs)</li> <li>• Obesity</li> <li>• Familial predisposition</li> <li>• Environmental exposures such as phthalates, polychlorinated biphenyl, and bisphenol A</li> <li>• Beef and other reds meats (1.7-fold) or ham (1.3-fold increased relative risk)</li> <li>• Vitamin D Deficiency</li> <li>• Increases in Glycemic index</li> <li>• Alcohol especially beer intake</li> </ul>

(AU Chiaffarino et al 1999, McWilliams MM et al 2017)

## Description and Histologic Variants



Uterine leiomyomas (UL) are usually spherical masses of tissue that can vary from a few millimeters to many centimeters in diameter.

They are characterized by increased proliferation of disordered smooth muscle cells, altered extracellular matrix (ECM) deposition, and enhanced responsiveness to sex steroid hormones.

## Definition of Benign versus Malignant variants

Leiomyoma variants are classified as benign or malignant based upon **histologic features**. Gross characteristics may **suggest** that a lesion is benign or malignant, but do not confirm a diagnosis. While some variants include lesions with extra-uterine extension or spread, this does not automatically confer a diagnosis of sarcoma or malignant neoplasm if the histology is benign-appearing.

On the other hand, some of the variants have histologic findings that make it difficult to define them as benign or malignant (eg, smooth muscle tumors of uncertain malignant potential).

- **Benign Smooth Muscle Neoplasms** (ie, leiomyomas of the usual histologic type or “**Garden-Variety**” leiomyomas) are defined as follows :
  - Low mitotic index (<5 mitoses per 10 high-power fields [HPF])
  - No cytologic atypia
  - No cell necrosis (apart from bland degeneration due to tumor ischemia)
  - Spindle-shaped cells that are uniform in size and shape
  - No intravascular component
  - Well-circumscribed mass
- **Smooth Muscle Tumors** are primarily **designated as Malignant** according to the presence and extent of three histologic characteristics :
  - Abundant mitoses ( $\geq 10$  per 10 HPF, depending on other characteristics)
  - Prominent nuclear atypia
  - Areas of coagulative tumor cell necrosis in a “geographic” (like islands on a map) fashion, so-called “**Tumor Cell Necrosis**”

(Quade BJ et al 2009)

The **distinction of leiomyosarcoma from other lesions** based on various complex combinations of these features was proposed based upon a large clinic-pathological series by Bell et al and is shown in the following table.

**Table 2 : Classification of problematic uterine smooth muscle tumors based on pathologic features**

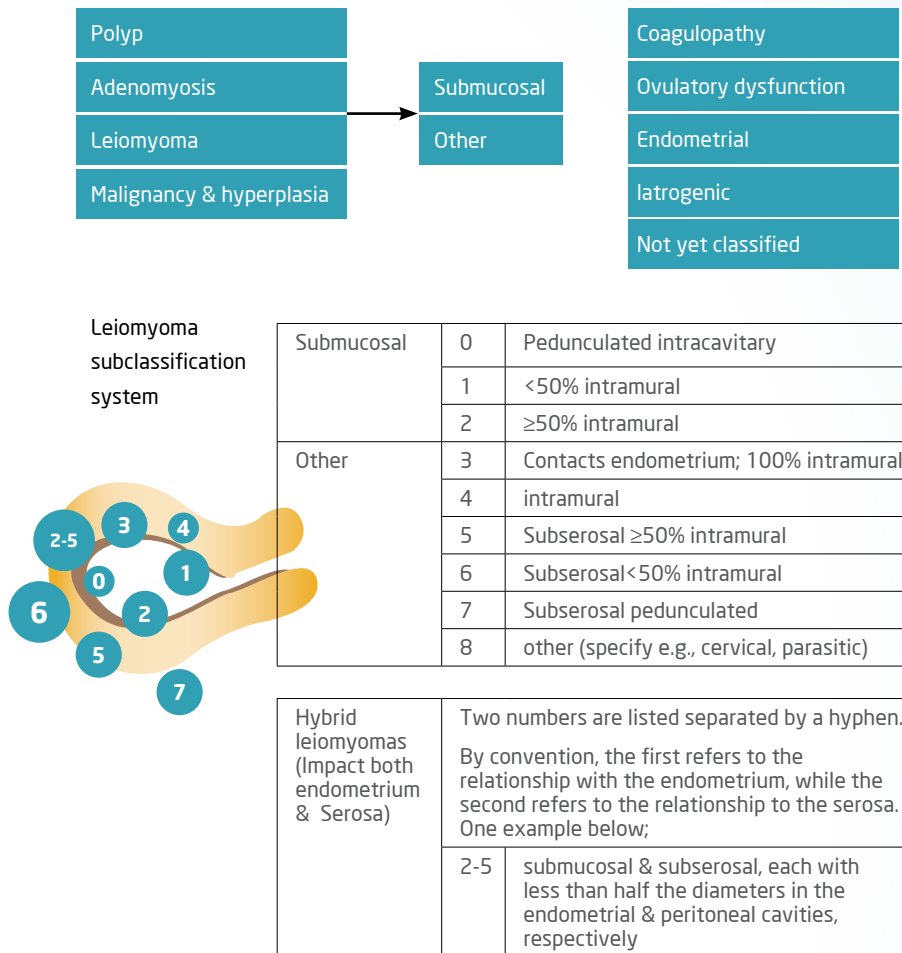
Group	MI (Per10HPF)	Atypia	Coagulative tumor cell necrosis	Designation	Metastatic or recurrent disease
I	$\geq 5$ to $< 20$	None or mild	None	Leiomyoma with increased MI	1/89
IIA	$< 10$	Diffuse, moderate or severe	None	Atypical leiomyoma with low risk percent or recurrence	2/46
IIB	$\geq 10$	Diffuse, moderate or severe	None	Leiomyosarcoma	4/10
III	$\leq 20$	Diffuse, moderate to severe	Present	Leiomyosarcoma	19/33
IVA	$< 10$	None to mild	Present	Smooth muscle tumor or low malignant potential, limited experience	1/4
IVB	$\geq 10$	None to mild	Present	Leiomyosarcoma	3/4
V	$\geq 1$ to $\geq 20$	Multifocal, moderate to severe	None	Atypical leiomyoma, limited experience	0/5

MI : mitotic index : HPF: high power field

Data from : Bell SW, Kempson RL, Hendrickson MR. Problematic uterine smooth muscle neoplasm, A clinicopathologic study of 213 cases. Am J Surg Pathol 1994; 18:535

## Classification

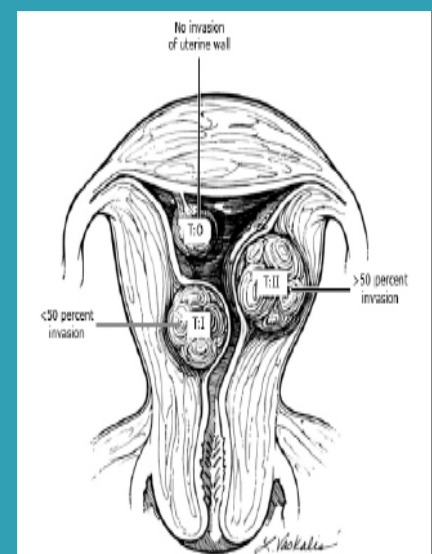
**Figure 2- ESGE/FIGO PALM-COEIN Classification.**



(Munro MG et al 2011)

**Figure 3**

**Submucosal leiomyoma position :**  
European Society of Hysteroscopy classification



**Baggish, MS, Valle, RF, Guedj, H. Hysteroscopy :**

Visual Perspectives of Uterine Anatomy, Physiology and Pathology. Philadelphia: Lippincott Williams & Wilkins, 2007. Copyright © 2007 Lippincott Williams & Wilkins.



## Symptoms

- Heavy or prolonged menstrual bleeding
- Bulk-related symptoms, such as pelvic pressure and pain
- Reproductive dysfunction (ie, infertility or obstetric complications)

**Abnormal Uterine Bleeding (AUB)** - Among symptomatic women with uterine fibroids, abnormal uterine bleeding (**AUB**) and **menstrual cramps** are the **most common symptoms** occurring in about 26 to 29 percent of all women. African American women reported higher rates at 37 to 42 percent.

**(Stewart EA et al 2013)**

The presence and degree of uterine bleeding (**AUB**) are determined, in large part, by the **location of** the fibroid; **size** is of **secondary importance**.

1. **Submucosal myomas** that protrude into the uterine cavity (**eg, types 0 and 1**) are most frequently related to significant heavy menstrual bleeding. **(Wegienka G et al 2003 )**
2. **Intramural myomas** are also commonly associated with heavy or prolonged menstrual bleeding, but **subserosal** fibroids are not considered a major risk for heavy menstrual bleeding.
3. **Cervical fibroids** that are close to the endo-cervical canal may be related to AUB

**Bulk-related symptoms** - The myomatous uterus is enlarged and irregularly shaped and can cause specific symptoms due to pressure from myomas at particular locations. These symptoms and findings include pelvic pain or pressure, urinary tract or bowel obstruction, or venous compression.

Fibroids associated with **hydronephrosis** were larger with an average largest fibroid of **6cm** and a **uterine size of 18 weeks**.

**(Fletcher HM et al 2013)**

**Fibroid Degeneration or Torsion** - Infrequently, fibroids cause **acute pain from breaking down** of the fibroid tissue (eg, carneous or red degeneration) or **torsion** of a pedunculated tumor.

Fibroid degeneration typically results in pelvic pain and may be associated with a low-grade fever, uterine tenderness on palpation, elevated white blood cell count, or peritoneal signs. The discomfort resulting from degenerating fibroids is self-limited, lasting from days to a few weeks, and usually responds to nonsteroidal anti-inflammatory drugs.

In cases where the **etiology of pain is unclear**, **pelvic MRI with gadolinium** can be useful to make the diagnosis of degeneration since **regions of degeneration** within fibroids do **not** have **enhancement** following contrast administration.

**(Laughlin SK et al 2011)**

## Fibroids, Infertility and ART - Controversies ...

Although there is a significant proportion of couples with unexplained infertility and a well-known common prevalence of uterine fibroids in reproductive-aged women, it has been unclear whether non-cavity-distorting fibroids contribute to an inability to conceive or negatively impact pregnancy. Thus, **couples should complete a full infertility evaluation before addressing the role of leiomyomas** in their infertility.

**Submucosal** ULs also lead to **lower pregnancy, implantation, and delivery rates** in women undergoing **IVF**. There is evidence of cross talk from UL to adjacent endometrial cells that can lead to **decreased endometrial receptivity**.

**(Cook H et al 2010)**

**Eldar-Geva et al** found that **implantation rates were lower** for women with intramural and submucous fibroids, **even if no deformity of the uterine cavity existed**. The investigators speculate that the presence of intramural or sub-mucous fibroids can cause endometrial changes or changes in vascularization through secretion of growth or angiogenic factors, through changes in the surrounding myometrial contractility, or through mechanical pressure. The presence of **sub-serosal myoma** had no effect on implantation rates. **(Eldar-Geva T et al 1998)**

**Hart and colleagues** studied a similar cohort of women undergoing **IVF** with **intramural fibroids less than 5cm** in size, (n=112) compared with control women with no fibroids (n=322). In this study, pregnancy, implantation and ongoing pregnancy rates were reduced significantly to 23.3, 11.9 and 15.1%, respectively, compared with 34.1, 20.2 and 28.3%, respectively, in the control group. After controlling for age and number of embryos transferred, they calculated a **50% decrease in ongoing pregnancy rate** with an intramural fibroid that was up to 5 cm in diameter (OR: 0.46; CI: 0.24-0.88). **(Hart R et al 2001)**

**Styer et al.** analysed the association of **non-cavity-distorting uterine fibroids** and pregnancy outcomes after ovarian stimulation-intrauterine insemination (**OS-IUI**) in couples with unexplained infertility in a recent prospective, randomized, multicenter clinical trial (**AMIGOS**) and found **no differences** were observed in conception and **live birth rates** in women with non-cavity-distorting fibroids and those without fibroids. However, found an increased rate of pregnancy loss in African American women with fibroids and thus raised the question of whether there are **race-specific pregnancy outcomes** associated with non-cavity-distorting fibroids after conception with OS-IUI ?

Hence, for women with **intramural fibroids** that **do not distort** the **uterine cavity**, **other sources of infertility should be addressed prior to a myomectomy.**

**(Styer AK et al 2017)**

## Diagnosis

The **clinical diagnosis** of uterine leiomyomas is made based upon a **detailed history, pelvic examination** and **pelvic ultrasound** findings consistent with a uterine leiomyoma. Characteristic symptoms further support the clinical diagnosis, although many women are asymptomatic. A **definitive diagnosis by pathology** evaluation **is not obtained in all cases but should be pursued** if there is reason to be suspicious that the uterine mass may not be a fibroid, but rather may be a uterine pre-cancer or cancer.

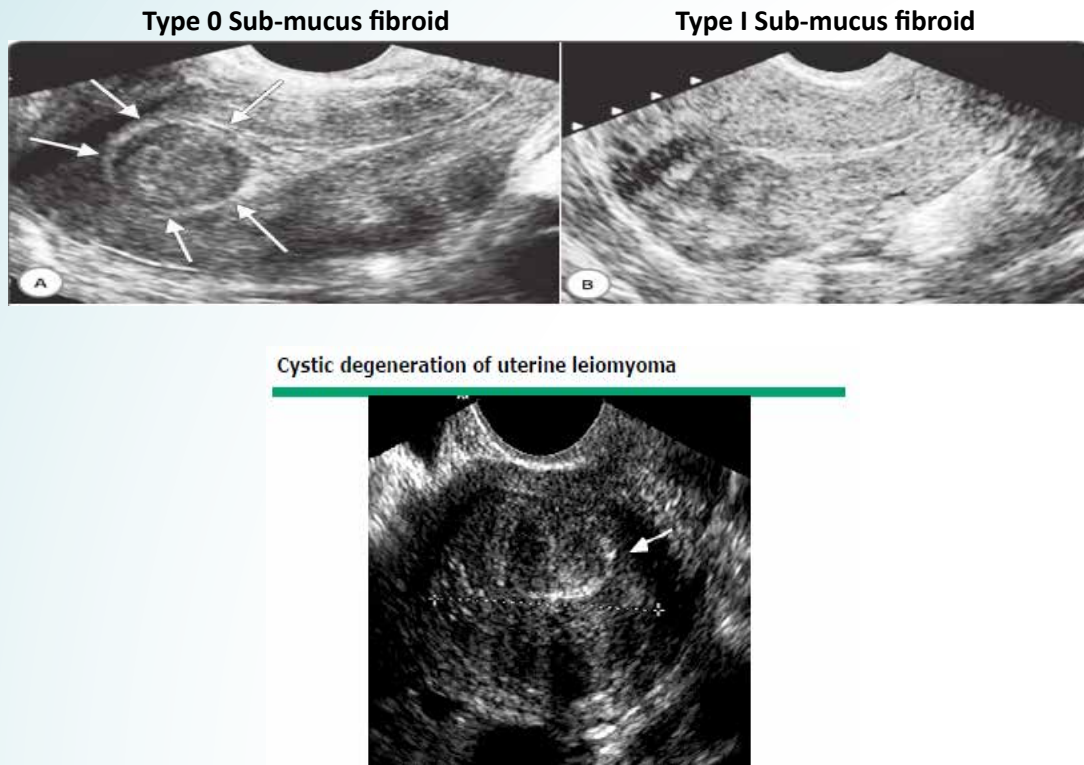
**Pelvic ultrasound** is the **imaging study of choice** for uterine leiomyomas, based on the ability to visualize genital tract structures and cost-effectiveness. Ultrasound is typically performed in all patients, and then other studies are ordered depending on the clinical indications.

A good **3D/4D vaginal ultrasound** 3D is also useful for the exact localization of the fibroid and precisely estimates the relationship between sub-mucus fibroid and endometrial cavity.

Benacerraf et al demonstrated that the **3D coronal view** was useful in **more accurately determining the specific location of fibroids** (i.e., submucous vs intramural) in 24% of patients using the coronal view.

**(Benacerraf BR et al 2008)**

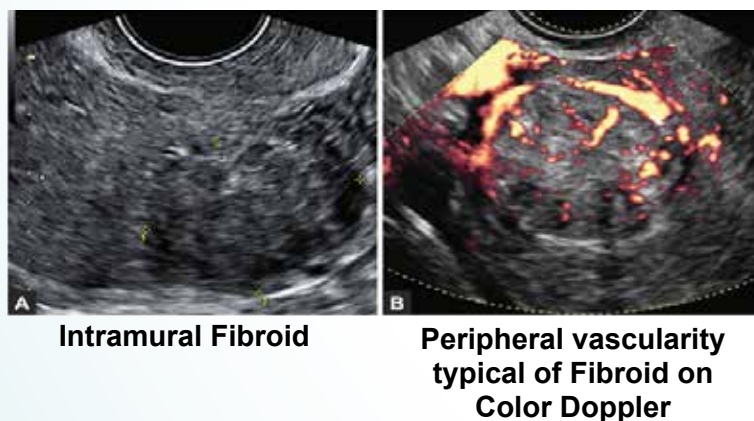
## Image 1



Courtesy Jorge Londono, MD.

**Vascular density, ischemic necrosis, and histologic cellular activity score** have been found to be statistically significantly associated with some **3D power Doppler ultrasound indices**.

## Image 2



**Minsart et al** found a **high histologic cellular activity score, combining hyper-cellularity, a fibrosclerosis rate less than 25% and positive Ki-67 staining**, to be statistically related in multivariate analyses to **high 3D power Doppler VI** in spherical samples and **vascularization flow index (VFI)**. (Minsart AF et al 2012)

If there is an **intra-cavitary leiomyoma** (submucosal or intramural that protrudes into the uterine cavity), and if the percent of the fibroid that is within the endometrial cavity is not clearly ascertained



(and could alter care) then **saline infusion sonography or hysteroscopy may be used to evaluate the uterine cavity.**

Transvaginal ultrasound has **high sensitivity (95 to 100 percent)** for detecting myomas in uteri **less than 10 gestational weeks' size.**

(Dueholm M et al 2002)

On imaging, **calcification** in a fibroid generally implies that it has **degenerated**. These calcifications can be seen on plain film as "popcorn" calcifications in the pelvis. On ultrasound, the calcifications may appear as clumps or rim-like calcifications within a mass.

## Evaluate the cavity

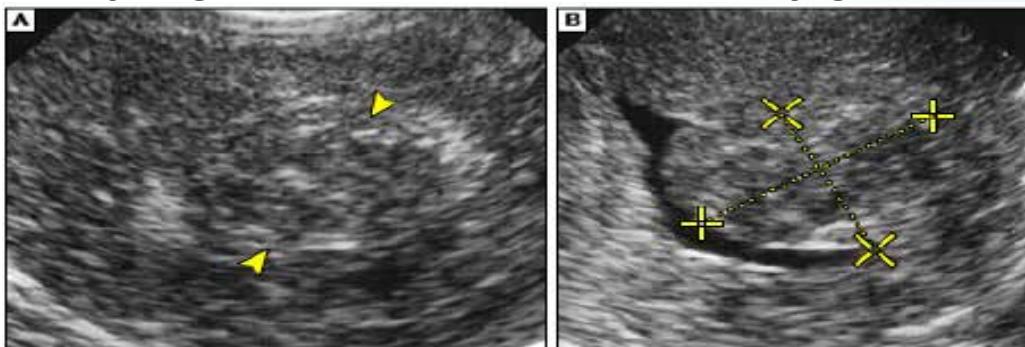
### • Saline Infusion sonography (SonoHysterography) –

Saline infusion sonography is an imaging study in which pelvic ultrasound is performed while saline is infused into the uterine cavity. Use of this technique allows identification of **submucosal lesions** (some of which may not be seen on routine ultrasonography) and **intramural myomas that protrude into the cavity** and characterizes the extent of protrusion into the endometrial cavity. This is shown in image below :

### Image 3

(A) Sagittal transvaginal sonogram shows hypoechoic endometrial thickening (arrowheads).

(B) Sagittal Sonohysterogram shows submucosal fibroid with thin overlying endometrium (cursors).



Sonohysterographic evaluation. AJR Am J Roentgenol 2001; 176:617. Copyright © 2001

- **Hysterosalpingograms ( HSG)** can also sometimes **show the distortion of the endometrial cavity** but are best reserved for the woman needing **assessment of fallopian tube** patency for fertility.
- **Hysteroscopy** - Hysteroscopy is useful not only for **visualizing** the endometrial cavity but also carrying out **hysteroscopic resection** of a submucosal fibroid if previous ultrasound has already confirmed size and proximity to the endometrium. However, when the **fibroid abuts the endometrium or protrudes into the myometrium**, the **depth of penetration cannot be ascertained hysteroscopically**. Additionally, hysteroscopy **less accurately predicts the size of the myoma compared with ultrasound and sonohysterography**.

(Cicinelli E et al 1995)

## Additional Tests

- Magnetic resonance imaging (**MRI**) may be used if ultrasound findings are not sufficient for **surgical planning** or if the **diagnosis is uncertain**, that is, if there is a **suspicion** of uterine **sarcoma** or **adenomyosis**. Due to the expense of this modality, its use is best reserved for **procedural planning** for **complicated** procedures. **IV Gadolinium** based contrast is usually not required, however when

administered **fibroids enhance later** than healthy myometrium.

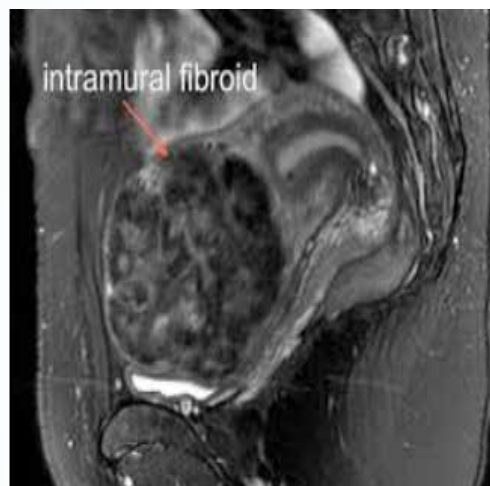
However a study by **Dueholm et al comparing transvaginal ultrasound with MRI**, reports a sensitivity and specificity of **100% and 91%, respectively, for MRI**, which is **currently** considered to be the **most accurate** imaging modality for the diagnosis and **characterization of intramural and submucous fibroids**. Unfortunately, few studies use MRI preoperatively for diagnosis, thus leading to potential underreporting of intra-cavitary involvement.

**(Dueholm M et al 2001)**

On **MRI** one third of fibroids usually have a **hyperintense rim on T2-weighted images** (as demonstrated in the image below) as a result of dilated veins, lymphatics, or edema.. Data suggest that **less stiff fibroids** appear **lighter on T2-weighted MRI**, while stiffer fibroids are darker on T2-weighted images.

**(Jondal DE et al 2017)**

**Image 4**



For women with **type 3 through 6** uterine fibroids, an **MRI** can help the surgeon **plan for laparoscopic myomectomy** to know the expected depth into the myometrium. It can also be useful **before uterine artery embolization** since imaging patterns predict uterine artery embolization outcome.

**(Vedantham S et al 2002)**

- **Computed tomography (CT)** has **little clinical utility** in delineating the position of fibroids relative to the endometrium or myometrium. Although Fibroid **calcifications** may be **more visible** on CT scans than on conventional radiographs because of the superior contrast differentiation achieved with CT scanning.

**(Bradley LD et al 2000)**

- Fibroids that are thought to be causing **urinary tract obstruction**, a **renal ultrasound** is advisable to assess for hydronephrosis.
- In certain cases of **Broad ligament** or **Cervical fibroids** an **IVP pre-operatively** helps with localisation of the ureters in relation to the fibroid.

## **Differential Diagnosis**

The differential diagnosis of uterine leiomyomas includes other conditions that cause uterine enlargement, abnormal uterine bleeding (AUB), pelvic pain, or infertility. It is important to note that leiomyomas are a common condition, and other coexisting conditions may be the etiology of the presenting symptoms.

The differential diagnosis of an enlarged uterus includes both benign and malignant conditions:

## Myometrial lesions :

- Benign leiomyoma.
- Adenomyosis (diffuse infiltration of the myometrium) or adenomyoma.
- Leiomyoma variant.
- Leiomyosarcoma.
- Metastatic disease - This is very rarely the cause of an enlarged uterus and typically from another reproductive tract primary; these lesions are likely to be myometrial but may invade the endometrium

## Endometrial lesions :

- Endometrial polyp - These tend to be small and are unlikely to cause an enlarged uterus.
- Endometrial carcinoma (may invade into the myometrium) or hyperplasia.
- Carcinosarcoma - Considered an epithelial neoplasm.
- Endometrial stromal sarcoma (mimics endometrium but invades the myometrium).
- Pregnancy
- Hematometra (blood within the uterine cavity, usually following an intrauterine procedure, eg, dilation and curettage)

## Treatment

Relief of symptoms (eg, abnormal uterine bleeding, pain, pressure) is the major goal in management of women with significant symptoms. The type and timing of any intervention should be individualized, based upon factors such as:

- Type and severity of symptoms
- Size of the myoma(s)
- Location of the myoma(s)
- Patient age
- Reproductive plans and obstetrical history

**Prophylactic therapy to avoid potential future complications** from myomas or their treatment is **not recommended** because we don't have reliable predictors of progression.

Data suggest **medical therapy** provides adequate symptom relief in some women, primarily in situations where bleeding is the dominant or only symptom. In general, **75 percent** of women get **some improvement over one year of therapy**, but **long-term failure rates** are **high**.

A systematic review by **Marjoribanks et al** observed that in trials where women were randomly assigned to **oral medical therapy**, **almost 60 percent had undergone surgery by two years**.

**(Marjoribanks J et al 2006)**

**Surgery is the mainstay of therapy** for leiomyomas and hysterectomy remains the most utilized procedure.



**Table 3 - Briefly summarises the various treatment modalities-**

Treatment	Description	Disadvantage	
<b>Expectant management</b>	About <b>3-7%</b> of untreated fibroids can <b>regress</b> over <b>6 mths - 3years</b> in premenopausal women. If symptoms appear then evaluate accordingly <b>(Vilos Ga et al 2015)</b> <b>Clinical surveillance</b> for <b>asymptomatic</b> women	<b>No high quality data</b> regarding <b>follow-up</b> of fibroids in patients who are asymptomatic or who decline medical or surgical treatment.	
Medical Therapies			
	Description	Disadvantage	Advantage
<b>GnRh agonists</b>	Preoperative treatment to decrease size before surgery / ART / peri-menopause  <b>Side effects</b> of long-term GnRH agonist administration can be <b>minimized</b> during therapy by giving <b>addback</b> therapy with low dose estrogen-progestin <b>after the initial phase of downregulation.</b>	<b>Hypoestrogenism</b> symptoms-including hot flashes, sleep disturbances, vaginal dryness, myalgias and arthralgias, and possible impairment of mood and cognition.  <b>Bone loss</b> leading to osteoporosis after long-term use(12+ months)  After <b>discontinuation</b> of therapy with GnRH agonists, menses returns in 4-8 weeks and <b>uterine size</b> returns to <b>pre-treatment</b> levels <b>within 4-6 months.</b>	Significant <b>reduction - 35 to 60 percent in uterine size</b> within three months and improvement in anaemia.  <b>(Carr BR et al 1993)</b>
<b>GnRh antagonists</b>	As above	These agents are marketed to at doses used in routine ART and <b>long-acting preparations</b> are <b>not available</b> . Thus, treatment of leiomyomas is cumbersome due to the need for daily injections.	Advantage of antagonists over agonists is the <b>rapid onset</b> of clinical effects without the characteristic initial flare-up observed with GnRH agonist treatment.  Daily subcutaneous injection of the GnRH antagonist ganirelix results in a <b>29% reduction</b> in fibroid volume within 3 weeks  <b>(Flierman PA et al 2005)</b>

<b>Combined COC pills</b>	Mechanism of action is via endometrial atrophy.	COC related side effects	<p>Reduces blood loss from fibroids and particularly <b>helps</b> women with <b>coexisting problems</b> (eg, dysmenorrhea or oligoovulation)</p> <p><b>17% reduction</b> in <b>growth</b> in <b>current users</b>.</p> <p><b>(Qin J et al 2013)</b></p> <p>However, this approach should be <b>reassessed</b> if a woman has <b>exacerbation</b> of bulk-related symptoms or does <b>not respond</b> to a <b>three- to six-month trial period</b></p>
<b>Progestogen only pills</b>	Currently no data to discern the effectiveness of progestin-only contraceptive steroids specifically for treatment of leiomyomas, but cause endometrial atrophy	Progesterone related side effects	<p>They can be considered for treatment of mild symptoms, especially for women who need contraception.</p> <p>Evidence from cohort studies that these agents are associated with a <b>decreased risk of leiomyoma formation</b></p> <p><b>(Venkatachalam S et al 2004)</b></p>
<b>LNG IUS</b>	Mechanism of action is via endometrial atrophy.	Presence of intra-cavitary leiomyomas amenable to hysteroscopic resection is a strong relative contraindication to use	<p>Study found that women with at least <b>1 fibroid &lt;5 cm</b>, with <b>&lt;50%</b> of the <b>fibroid</b> in the <b>endometrial cavity (type 2)</b>, had a <b>90% reduction in blood loss</b> and an increase in hemoglobin levels <b>1 year</b> after insertion of an LNG-IUS</p> <p><b>(Soysal S et al 2005)</b></p>

Selective progesterone receptor modulators ( SPRM's)			
<b>Ulipristal Acetate (UPA)</b>	<p>They seem to interrupt angiogenesis and growth signals from progesterone that involves TGF-<math>\beta</math> signaling causing reduction in the size of the fibroid</p> <p>Recent <b>MHRA warning</b> for use (<b>Feb 2018</b>) in view of <b>severe liver disease</b> found in some women and advise monthly LFTs</p>	<p>Headaches , Breast Tenderness</p> <p>Reversible changes occur in endometrium known as PRM-associated endometrial changes (<b>PAECs</b>).</p> <p>Therefore <b>intermittent use</b> is advised.</p> <p>Usually for up to <b>four three-month courses</b> separated by a <b>spontaneous withdrawal</b> menstrual flow or one brought on by norethindrone acetate (<b>Donnez J et al 2014</b>)</p>	<p>Decreased blood loss (<b>faster action than GnRh agonists</b>),</p> <p><b>More than 13 weeks</b> of treatment with oral Ulipristal acetate, <b>5 mg</b> daily, <b>controlled excessive uterine bleeding</b> in at least <b>90%</b> of patients and was shown to be <b>non-inferior</b> to <b>leuprolide</b> acetate injected monthly over <b>3 months</b>.</p> <p>Uterine volume reduction was <b>maintained for at least 6 months</b> after <b>discontinuation</b> of treatment.</p> <p>(<b>Croxtall JD et al 2012</b>)</p>
<b>Vilaprisan</b>	Stronger antiprogestogenic effect than UPA	Currently phase III trials underway	<p>In the <b>phase 2 ASTEROID-1 study</b>, women with UFs received varying doses(0.5 mg, 1mg, 2mg and 4mg) of vilaprisan or placebo for one 12-week cycle. By the end of the treatment cycle, <b>87% to 92% of patients achieved amenorrhea</b>. Fibroid volume reductions, decreases in fibroid-related symptoms, and increases in QoL scores were also seen.</p> <p>(<b>Bradley L et al 2016</b>)</p>
<b>Mifepristone</b>		<p><b>Not FDA approved</b> for fibroid use</p> <p>Reversible changes occur in endometrium known as PRM-associated endometrial changes (<b>PAECs</b>).</p>	<p>It <b>reduces</b> uterine volume by 26 to 74 percent in women with leiomyomas, <b>comparable</b> to the reduction observed with <b>GnRH agonists</b>.</p> <p>Regrowth occurs slowly following cessation of the drug</p> <p>(<b>Steinauer J et al 2004</b>)</p>
Others			
<b>Raloxifene</b>	Selective Estrogen Receptor Modulators ( <b>SERMs</b> )	Unclear efficacy Risk of Venous thrombosis	<p>A small trial (25 patients) found raloxifene (180 mg/ day for three months) <b>inhibited leiomyoma growth</b> in premenopausal women compared to untreated controls, in whom leiomyomas continued to enlarge.</p> <p>(<b>Jirecek S et al 2004</b>)</p>



<b>Aromatase Inhibitors</b>	Block synthesis of estrogen	Insufficient evidence for use Vaginal dryness/ Musculoskeletal pain	<b>Small series</b> and one randomized clinical trial have described shrinkage of symptomatic leiomyomas and a decrease in leiomyoma symptoms in women in the menopausal transition given aromatase inhibitors <b>(Hilário SG et al 2009)</b>
<b>Anti-fibrinolytic agents</b>	Useful in the treatment of idiopathic heavy menstrual bleeding	Not been well studied in leiomyoma-related heavy menstrual bleeding	Tranexamic acid is widely used worldwide and in the United States is FDA-approved for the treatment of heavy menstrual bleeding <b>(AUB)</b>
<b>Future Treatments</b>			
<b>Epigallocatechin gallate (EGCG) - green tea extract</b>	<b>Green Tea Catechins</b> are epigallocatechin-3-gallate (EGCG), epigallocatechin (EGC), epicatechin-3-gallate (ECG), and epicatechin. EGCG appears to <b>block</b> each stage of <b>tumor genesis</b>	Need robust <b>clinical trials</b>	The potential effect and mechanisms of EGCG action on human leiomyoma cells was studied and it was found that <b>EGCG inhibits their proliferation and induces apoptosis.</b> <b>(Khan N et al.2006)</b>
<b>Lanreotide</b>	Long-acting <b>somatostatin analog</b> & has been shown to <b>reduce growth hormone secretion.</b> <b>Leiomyoma</b> tissue expresses <b>higher levels of IGF-I/IGF-II</b> receptors compared to normal adjacent myometrium	<b>Lack of clinical trials</b> which test the long term use of somatostatin analogs along with the severe and <b>adverse health implications</b> such as decreased life expectancy due to <b>accelerated heart disease</b> may hinder its future use	<b>42% mean myoma volume reduction</b> within a <b>3-month period.</b> <b>(De Leo V et al, 2001)</b>
<b>Surgical Management</b>			
<b>Hysterectomy ( Abdominal/ Vaginal/ Laparoscopic)</b>	Definitive treatment Main advantage of hysterectomy over other invasive interventions is that it eliminates both current symptoms and the chance of recurrent problems from leiomyomas	Major surgery/ anaesthesia risks	Laparoscopic approach has faster recovery and lesser morbidity

<b>Hysteroscopic Myomectomy</b>	<p>Preserves fertility</p> <p>It is <b>optimal</b> for <b>Type 0 or 1 Submucosal</b> fibroids <b>&lt;3 cm</b> where <b>&gt;50%</b> is <b>intracavitary</b></p> <p>(Camanni M et al 2010)</p> <p>May be <b>combined with laparoscopic</b> approach</p> <p>Faster recovery</p>	<p>Surgery/ anaesthesia risks</p> <p>May need <b>2-staged</b> procedure</p>	<p><b>Hysteroscopic resection</b> of <b>sub-mucous fibroids</b> also can significantly <b>reduce heavy menstrual bleeding</b> in <b>82%</b> of women with sub-mucous pedunculated fibroids (<b>type 0</b>), <b>86%</b> with sessile fibroids (<b>type 1</b>), and <b>68%</b> with intramural fibroids (<b>type 2</b>).</p> <p>(Vercellini P et al 1999)</p>
<b>Myolysis ( Laparoscopic)</b>	<p>Laparoscopic thermal, radiofrequency, or cryoablation (cryomyolysis) of leiomyoma tissue</p> <p>Now approved by the US Food and Drug Administration for use</p>	<p>Localized tissue destruction without suturing may <b>increase</b> the chance of subsequent <b>adhesion</b> formation or <b>rupture</b> during pregnancy</p> <p>(Arcangeli S et al 1997)</p>	<p>Intraperitoneal ultrasound diagnosis is used with this technique to optimize detection of fibroids.</p> <p>In a single randomized trial, radiofrequency ablation resulted in a shorter length of stay and less blood loss.</p> <p>(Brucker SY et al 2014)</p>
<b>Others</b>			
<b>UAE</b>	<p>Interventional radiological approach to occlude uterine arteries</p>	<p>Robust studies needed regarding fertility outcomes after UAE, thus <b>caution in women desiring fertility</b></p> <p>Risk of <b>post-embolization syndrome</b></p> <p>Women with larger uteri and/or more leiomyomas at baseline are at greater risk of failure and re-intervention.</p>	<p>Minimally invasive/ avoids surgery</p> <p>It is an effective option for women who wish to <b>preserve their uterus</b> and are <b>not</b> interested in <b>optimizing future fertility</b>.</p> <p>It results in <b>shrinkage</b> of myomas of approximately <b>30 to 46 percent</b></p> <p>(Gupta JK et al 2006)</p>
<b>MR guided focused ultrasound (MRgFUS)</b>	<p>In situ destruction by high intensity ultrasound waves</p> <p><b>Non-invasive thermos-ablative technique</b> converges multiple waves of ultrasound energy on a small volume of tissue, which leads to its thermal destruction, and can be performed as an <b>outpatient procedure</b></p>	<p>Robust studies needed regarding fertility outcomes after MRgFUS, thus <b>caution</b> and detailed counselling in women <b>seeking fertility</b>.</p> <p>This system is <b>not indicated</b> for leiomyomas which are <b>resectable</b> with a <b>hysteroscope</b>, <b>heavily calcified</b>, or <b>when intervening bowel or bladder could be damaged</b> by treatment.</p> <p><b>Maximum size</b> of fibroids that can be treated with this method is <b>uncertain</b></p>	<p>Modest symptom relief</p> <p>Shorter recovery</p> <p>It appears that MRgFUS results in a <b>reduction</b> in myoma volume of approximately <b>37 to 40 percent</b>.</p> <p>(Funaki K et al 2009)</p>



# Part - 2

Frequently Asked Questions ?



## Frequently Asked Questions ?

### Question 1) What potential mechanisms are involved in small intra mural fibroids affecting fertility ?

**Answer 1)** The mechanisms by which small intramural fibroids exert their adverse effect on the success rate of IVF are unclear but may include :

- Altered myometrial contractility
- Uterine vascular distortion
- Endometrial inflammation, thinning and atrophy
- Exerting an adverse effect on gamete migration
- Alterations in gene expression

(Khalaf Y et al 2006)

### Question 2) What type of fibroids affect fertility ?

**Answer 2)** There are no well-designed studies that provide high-quality data on whether leiomyomas adversely affect pregnancy outcome.

Leiomyomas that **distort the uterine cavity** (sub-mucosal or intramural with an intra-cavitary component) result in **difficulty conceiving a pregnancy** and an **increased risk of miscarriage**. In contrast, **sub-serosal** fibroids **do not impact fertility**.

A **meta-analysis** of the effect of fibroids on fertility found that **sub-mucous fibroids** causing distortion of the uterine cavity **reduced ongoing pregnancy/live birth rates by 70%** (relative risk 0.32; 95% confidence interval, 0.12-0.85) and that **fibroid resection** increased ongoing **pregnancy** and **live birth rates**.

(Pritts EA et al 2009)

### Question 3) What is impact of small non-cavity distorting intramural fibroids on ART ?

**Answer 3)** The role of **intramural** fibroids in infertility is **controversial**.

A prospective trial of 434 women undergoing IVF/intracytoplasmic sperm injection demonstrated a **significant reduction in clinical and ongoing pregnancy rates** and an increase in early pregnancy loss with **intramural fibroids less than or equal to 5 cm**. However, live birth rates were not reported.

(Hart R et al 2001)

**Khalaf et al. compared pregnancy outcomes** in women with (n = 122) and without small **intramural fibroids less than or equal to 5 cm** (control, n = 322) in a prospective comparative study of women undergoing their first three IVF cycles. Over a 12- month period, the investigators reported a 40%-45% reduction in cumulative live birth rates in women with fibroids

(Khalaf Y et al 2006)

A recent retrospective study by **Christopoulos G**, concluded that **non-cavity distorting** intramural myomas **negatively** influence clinical pregnancy rate and live birth rate when compared to matched controls. The deleterious effect on IVF outcome was **significant** in women with **2 or more myomas** or when **size of myoma is > 3cm**.

The study **did not** reveal any **significant** impact in women with **myoma size < 30mm**.

(Christopoulos G et al.2017)

## Question 4) Is myomectomy recommended before IVF for non-cavity distorting intramural fibroids ?

**Answer 4)** Despite the growing body of evidence in favour of a negative impact of intramural fibroids on IVF/ICSI outcome, it is **unclear whether this impact can be reversed by myomectomy**.

Women with **large sub-serosal or intramural fibroids** have been shown to have **increased pregnancy and delivery rates** and **decreased miscarriage rates** **after myomectomy**.

(Bulletti C et al 2004)

However exposure of women with **small intramural fibroids (<5cm)** to the risks of myomectomy with the **sole aim of improving reproductive performance** remains **controversial**.

(Surrey ES et al 2003)

Gianaroli et al., suggested that patients with **small non cavity distorting intramural fibroids attempting IVF** should be counselled that they **have similar outcome** to those with **no fibroids**.

(Gianaroli L et al 2005)

## Question 5) What complications can occur in pregnancy due to fibroids ?

**Answer 5)** Most pregnant women with fibroids **do not have any complications** during pregnancy related to the fibroids. However, when complications occur, **painful degeneration is the most common** complication and there also appears to be a **slightly increased** risk of complications such as **miscarriage, premature delivery, abnormal fetal position, and placental abruption**.

In 10 to 40% of pregnancies with UL present, complications occur and **miscarriage** is up to **twofold higher** in women with **symptomatic UL**. In addition, it has been suggested that **sub-mucosal UL** may **disrupt normal uterine peristaltic movements and contractility**, impeding sperm arrival at the oviducts, embryo movement into the uterus, or causing **increased contractions leading to preterm labor**.

(Cook et al, 2010)

**Sub-mucosal** and **retro-placental** fibroids and fibroids with **volumes >200 mL** (corresponding to **7-8 cm** diameter) are associated with the **highest risk of abruption**

(Rice JP et al 1989)

## Question 6) What is the role of Ulipristal in management of fibroids?

**Answer 6)** Ulipristal acetate is a Progesterone Receptor Modulator (**PRM**) that is approved outside the United States both for **three months of preoperative** therapy and **short intermittent courses interrupted by menstruation** (European Conformity [CE mark] and Canadian drug authority).

A randomized trial by **Donnez et al** included 307 women with menorrhagia and a uterus that was  $\leq 16$  weeks of gestation size. Participants were assigned to **13 weeks** of therapy with either **ulipristal** acetate (oral, 5 mg or 10 mg per day) or the **GnRH-agonist leuprolide** acetate (intramuscular, 3.75 mg monthly). **Resolution of menorrhagia** was achieved **more quickly in the ulipristal** groups (approximately six days compared with 30 days for leuprolide). Women treated with ulipristal had a significantly **lower frequency of moderate to severe hot flashes** (in the ulipristal acetate groups, 5 mg: 11 percent; 10 mg: 10 percent versus leuprolide: 40 percent). The **reduction in uterine size was significantly lower** for the **ulipristal** groups (5 mg: 20 percent; 10 mg: 22 percent; leuprolide: 47 percent).

The **PEARL Trial III** concluded that repeated **3-month UPA courses** **effectively** control bleeding and shrink fibroids in patients with symptomatic fibroids and all endometrial biopsies showed **benign histology without hyperplasia**.

(Donnez J et al 2014)

In **February 2018** the Medicines & Healthcare products Regulatory Agency (MHRA) advised of **new temporary safety measures for Esmya (ulipristal acetate)** following reports of **serious liver injury** in women using the medicine for uterine fibroids. They advise on **performing liver function tests at least once a month in all women currently taking Esmya** and to **stop Esmya treatment** in any woman who develops **transaminase levels more than 2 times the upper limit of normal**.

( **European Medicines Agency for healthcare professionals and the public (9 Feb 2018)**)

### **Question 7) What are the endometrial changes associated with PRM agents ?**

**Answer 7)** A unique pattern of endometrial changes has been observed following

treatment with PRMs termed **“Progesterone Receptor Modulator-Associated Endometrial Changes” (PAECs)**.

The most common histologic finding observed in women taking PRMs is **cystic glandular dilatation**, with both estrogen and progestin epithelial effects.

Spitz IM et al in their review suggested that in some cases the endometrial histology had been erroneously interpreted as showing hyperplasia whereas true endometrial hyperplasia and atypical hyperplasia was not seen following PRM therapy and **no woman developed endometrial carcinoma**.

(**Spitz IM et al 2009**)

### **Question 8) Is there a new oral antagonist that can be used for treatment of fibroids instead of the injection ?**

**Answer 8)** There is a new generation of oral GnRH antagonists in development that are likely to be **more acceptable** and appear to be **effective** and **well tolerated**, particularly with add-back estrogen and progestin therapy to mitigate hot flashes. In women with **heavy menstrual bleeding associated with fibroids**, **Archer et al** recently conducted one of the first randomized trials (n = 271) to evaluate these agents was a dose-finding study that also compared elagolix alone at varying doses with **elagolix** plus a continuous versus cyclic add-back estrogen and progestin therapy.

Menstrual blood loss (**MBL**) change from baseline was greater with elagolix alone compared with placebo (**range of mean decrease, elagolix: 72 to 98 percent** versus placebo, 8 to 41 percent); dose dependent reduction was highest with 300 mg twice daily. MBL reduction was greater with elagolix 300 mg twice daily alone (97 percent) than with 600 mg once daily (89 percent) or elagolix 300 mg twice daily plus add-back therapy (80 to 85 percent). **Hot flush** was the **most common adverse effect** and was highest with elagolix alone (46 to 63 percent) versus add-back regimens (19 to 27 percent).

(**Archer DF et al 2017**)

### **Question 9) Are there any potential disadvantages of pre-operative GnRh agonist use especially when myomectomy is planned ?**

**Answer 9)** Potential disadvantage with 3-4 mths pre-operative use can be **difficult enucleation/ loss of cleavage planes / increase risk of recurrence** due to the reduction of previously small fibroids into surgically undetectable ones.

Other possible concerns are the possibility of **delaying the diagnosis of leiomyosarcoma**, a **greater degree of tumor hyalinization** and the **potential risk of massive hemorrhage** stemming from tumor degeneration.

(**Farquhar C et al 2002**)



## Question 10) What is the STEP-W submucosal fibroid classification system ?

**Answer 10)** The **STEP-W classification** considers size, topography, extension of the fibroid base, depth of fibroid penetration, and the lateral wall involvement.

Step-w submucosal fibroid classification system						
	Size (cm)	Topography	Extension of the Base	Penetration	Lateral wall	Total
0	<2	Low	<1/3	0	+1	
1	>2 to 5	Middle	>1/3 to 2/3	<50%		
2	>5	Upper	>2/3	>50%		
Score	+	+	+	+	+	
Score	Group	Complexity & therapeutic options				
0 to 4	I	Low-complexity hysteroscopic myomectomy				
5 to 6	II	High-complexity hysteroscopic myomectomy, consider two-step hysteroscopic myomectomy				
7 to 9	III	Consider alternatives to the hysteroscopic technique				
Stepw: size, topography, extension, penetration, wall: GnRH: gonodotropin-relesing hormone						
Reproduced from: Lasmar RB, Xinmei Z, Indman PD, rt al. Feasibility of a new system of classification of submucous myomas: a multicenter study, Fertil steril 2011, 95:2073. Table used with the permission of Elsevier Inc.						

Each factor is assigned a point value. A **low score of 0 to 4** (low complexity) is associated with **safety and successful** removal of the fibroid in one hysteroscopic setting.

A **score of 5 or 6** is considered **high complexity**, and may require a two-stage hysteroscopic procedure. A score of **7 to 9** is considered **not amenable to treatment hysteroscopically**

(Lasmar RB et al 2011)

## Question 11 ) What is the current opinion regarding power morcellation ?

**Answer 11)** The US FDA and ACOG recommends **caution** and emphasises the importance of **informed written consent** and should **not** be performed in women with **risk factors** or **suspicion** of **uterine cancer**.

(ACOG Power morcellation and occult malignancy in gynecologic surgery 2014)

## References

1. American College of Obstetricians and Gynecologists. Power morcellation and occult malignancy in gynecologic surgery: a special report. Washington, DC: American College of Obstetricians and Gynecologists; 2014:p. 1-6
2. Arcangeli S, Pasqualette MM. Gravid uterine rupture after myolysis. *Obstet Gynecol* 1997; 89:857
3. Archer DF, Stewart EA, Jain RL, et al. Elagolix for the management of heavy menstrual bleeding associated with uterine fibroids: results from a phase 2a proof-of-concept study. *Fertil Steril* 2017; 108:152.
4. AU Chiaffarino F, Parazzini F, La Vecchia C, Chatenoud L, Di Cintio E, Marsico S: Diet and uterine myomas. *Obstet Gynecol.* 1999;94(3):395
5. Baird DD, Hill MC, Schectman JM, Hollis BW. Vitamin d and the risk of uterine fibroids. *Epidemiology* 2013;24(3):447-453
6. Bell SW, Kempson RL, Hendrickson MR. Problematic uterine smooth muscle neoplasms. A clinicopathologic study of 213 cases. *Am J Surg Pathol* 1994; 18:535.
7. Benacerraf BR, Shipp TD, Bromley B. Which patients benefit from a 3D reconstructed coronal view of the uterus added to standard routine 2D pelvic sonography? *AJR Am J Roentgenol* 2008; 190: 626-629
8. Bradley LD, Falcone T, Magen AB. Radiographic imaging techniques for the diagnosis of abnormal uterine bleeding. *Obstet Gynecol Clin North Am* 2000; 27:245.
9. Bradley L, Ren X, Groettrup-Wolfers E, et al. Results of the ASTEROID (Assess Safety and Efficacy of Vilaprisan in Patients with Uterine Fibroids) 1 study: a phase 2, placebo-controlled dose finding study [ASRM abstract O-235]. *Fertil Steril.* 2016;106:e95
10. Brucker SY, Hahn M, Kraemer D, et al. Laparoscopic radiofrequency volumetric thermal ablation of fibroids versus laparoscopic myomectomy. *Int J Gynaecol Obstet* 2014; 125:261.
11. Bulletti C, De Ziegler D, LeviSetti P, Cincinelli E, Polli V and Stefanetti M; Myomas, pregnancy outcome and in-vitro fertilization. 2004;Ann N Y Acad Sci 1034,84-92.
12. Bulun SE. Uterinefibroids.NEngl J Med2013;369(14):1344-1355
13. Camanni M, Bonino L, Delpiano EM, Ferrero B, Migliaretti G, Deltetto F. Hysteroscopic management of large symptomatic submucous uterine myomas. *J Minim Invasive Gynecol.* 2010 Jan-Feb;17(1):59-65. doi: 10.1016/j.jmig.2009.10.013.
14. Carr BR, Marshburn PB, Weatherall PT, et al. An evaluation of the effect of gonadotropin-releasing hormone analogs and medroxyprogesterone acetate on uterine leiomyomata volume by magnetic resonance imaging: a prospective, randomized, double blind, placebo-controlled, crossover trial. *J Clin Endocrinol Metab* 1993; 76:1217.
15. Christopoulos G, Vlismas A, Salim R, Islam R, Trew G, Lavery S. Fibroids that do not distort the uterine cavity and IVF success rates: an observational study using extensive matching criteria. *BJOG.* 2017 Mar;124(4):615-621.
16. Cincinelli E, Romano F, Anastasio PS, et al. Transabdominal sonohysterography, transvaginal sonography, and hysteroscopy in the evaluation of submucous myomas. *Obstet Gynecol* 1995; 85:42.
17. Cook H, Ezzati M, Segars JH, McCarthy K. The impact of uterine leiomyomas on reproductive outcomes. *Minerva Ginecol* 2010; 62(3):225-236
18. Crabtree JS, Jelinsky SA, Harris HA, et al. Comparison of human and rat uterine leiomyomata: identification of a dysregulated mammalian target of rapamycin pathway. *Cancer Res* 2009;69-(15):6171-6178

19. Cramer SF, Patel A. The frequency of uterine leiomyomas. *Am J Clin Pathol* 1990; 94:435.
20. Croxtall JD. Ulipristal acetate: in uterine fibroids. *Drugs*. 2012;72:1075-1085
21. De Leo V, la Marca A, Morgante G, Severi FM, Petraglia F. Administration of somatostatin analogue reduces uterine and myoma volume in women with uterine leiomyomata. *Fertil Steril*. 2001;75(3):632-633.
22. Donnez J, Vázquez F, Tomaszewski J, et al. Long-term treatment of uterine fibroids with ulipristal acetate. *Fertil Steril* 2014; 101:1565.
23. Dueholm M, Lundorf E, Hansen ES, et al. Accuracy of magnetic resonance imaging and transvaginal ultrasonography in the diagnosis, mapping, and measurement of uterine myomas. *Am J Obstet Gynecol* 2002; 186:409
24. Dueholm M, Lundorf E, Hansen ES, Ledertoug S, Oleson F. Evaluation of the uterine cavity with magnetic resonance imaging, transvaginal sonography, hysterosonographic examination and diagnostic laparoscopy. *Fertil. Steril*. 2001; 76, 350-357
25. Eldar-Geva T, Meagher S, Healy DL et al: Effect of intramural, subserosal, and submucosal uterine fibroids on the outcome of assisted reproductive technology treatment. *Fertil Steril* 70: 687, 1998
26. Farquhar C, Brown PM, Furness S. Cost effectiveness of pre-operative gonadotrophin releasing analogues for women with uterine fibroids undergoing hysterectomy or myomectomy. *BJOG*. 2002;109:1273-80
27. Fletcher HM, Wharfe G, Williams NP, et al. Renal impairment as a complication of uterine fibroids: a retrospective hospital-based study. *J Obstet Gynaecol* 2013; 33:394.
28. Flierman PA, Oberye JJ, van der Hulst VP, de Blok S. Rapid reduction of leiomyoma volume during treatment with the GnRH antagonist ganirelix. *BJOG*. 2005;112:638-642.
29. Funaki K, Fukunishi H, Sawada K. Clinical outcomes of magnetic resonance-guided focused ultrasound surgery for uterine myomas: 24-month follow-up. *Ultrasound Obstet Gynecol* 2009; 34:584.
30. Gianaroli L, Grodts S, D'Angelo A, Magli MC, Brosens I, Ceterna C, Campo R and Ferraretti AP. Effect of inner myometrium fibroid on reproductive outcome after IVF. 2005; *Reprod Biomed Online* 10(4),473-477.
31. Gupta JK, Sinha AS, Lumsden MA, Hickey M. Uterine artery embolization for symptomatic uterine fibroids. *Cochrane Database Syst Rev* 2006; :CD005073
32. Hart R, Khalaf Y, Yeong CT, Seed P, Taylor A, Braude P. A prospective controlled study of the effect of intramural uterine fibroids on the outcome of assisted conception. *Hum Reprod* 2001;16:2411-7.
33. Hashimoto K, Azuma C, Kamiura S, et al. Clonal determination of uterine leiomyomas by analysing differential inactivation of the X-chromosome-linked phosphoglycerokinase gene. *Gynecol Obstet Invest* 1995; 40:204.
34. Hilário SG, Bozzini N, Borsari R, Baracat EC. Action of aromatase inhibitor for treatment of uterine leiomyoma in perimenopausal patients. *Fertil Steril* 2009; 91:240.
35. Jin C, Hu Y, Chen X, et al. Laparoscopic versus open myomectomy -- a meta-analysis of randomized controlled trials. *Eur J Obstet Gynecol Reprod Biol*. 2009;145:14-21.
36. Jirecek S, Lee A, Pavo I, et al. Raloxifene prevents the growth of uterine leiomyomas in premenopausal women. *Fertil Steril* 2004; 81:132
37. Jondal DE, Wang J, Chen J, Gorny KR, Felmler J, Hesly G, et al. Uterine fibroids: correlations between MRI appearance and stiffness via magnetic resonance elastography. *Abdom Radiol (NY)*. 2017 Sep 26



38. Khalaf Y, Ross C, El-Toukhy T, Hart R, Seed P, Braude P. The effect of small intramural uterine fibroids on the cumulative outcome of assisted conception. *Hum Reprod* 2006;21:2640-4.
39. Khan N, Afaq F, Saleem M, Ahmad N, Mukhtar H. Targeting multiple signal pathways by green tea polyphenol - epigallocatechin-3-gallate. *Cancer Res.* 2006;66(5):2500-2505.
40. Kim JJ, Kurita T, Bulun SE. Progesterone action in endometrial cancer, endometriosis, uterine fibroids, and breast cancer. *Endocr Rev* 2013;34(1):130-162
41. Lara PN Jr, Longmate J, Mack PC, et al. Phase II study of the AKT inhibitor MK-2206 plus erlotinib in patients with advanced non-small cell lung cancer who previously progressed on erlotinib. *Clin Cancer Res* 2015;21(19):4321-4326
42. Lasmar RB, Xinmei Z, Indman PD, et al. Feasibility of a new system of classification of submucous myomas: a multicenter study. *Fertil Steril* 2011; 95:2073
43. Laughlin SK, Stewart EA. Uterine leiomyomas: individualizing the approach to a heterogeneous condition. *Obstet Gynecol* 2011; 117:396.
44. Mäkinen N, Mehine M, Tolvanen J, et al. MED12, the mediator complex subunit 12 gene, is mutated at high frequency in uterine leiomyomas. *Science* 2011;334(6053):252-255
45. Marjoribanks J, Lethaby A, Farquhar C. Surgery versus medical therapy for heavy menstrual bleeding. *Cochrane Database Syst Rev* 2006; :CD003855.
46. McWilliams MM, Chennathukuzhi VM. Recent Advances in Uterine Fibroid Etiology. *Seminars in reproductive medicine.* 2017;35(2):181-189. doi:10.1055/s-0037-1599090
47. Minsart AF, Ntoutoume Sima F, Vandenhoute K, Jani J, Van Pachterbeke C. Does three-dimensional power Doppler ultrasound predict histopathological findings of uterine fibroids? A preliminary study. *Ultrasound Obstet Gynecol.* 2012 Dec. 40(6):714-20.
48. Munro MG, Critchley HO, Fraser IS. The FIGO classification of causes of abnormal uterine bleeding in the reproductive years. *Fertil. Steril.* 95(7), 2204-2208 (2011)
49. Parker WH. Etiology, symptomatology, and diagnosis of uterine myomas. *Fertil Steril* 2007;87(4):725-736
50. Pritts EA, Parker WH, Olive DL. Fibroids and infertility: an updated systematic review of the evidence. *Fertil Steril* 2009; 91:1215.
51. Qin J, Yang T, Kong F, Zhou Q. Oral contraceptive use and uterine leiomyoma risk: A meta-analysis based on cohort and case-control studies. *Arch Gynecol Obstet.* 2013;288:139-48.
52. Quade BJ, Robboy SJ. Uterine smooth muscle tumors. In: Robboy's Pathology of the Female Reproductive Tract, 2nd ed , Robboy SJ, Mutter GL, Prat J, et al (Eds), Churchill Livingstone Elsevier, Oxford 2009. p.474.
53. Rice JP, Kay HH, Mahony BS. The clinical significance of uterine leiomyomas in pregnancy. *Am J Obstet Gynecol* 1989; 160:1212.
54. Soysal S, Soysal M. The efficacy of levonorgestrel-releasing intrauterine device in selected cases of myoma-related menorrhagia: a prospective controlled trial. *Gynecol Obstet Invest.* 2005;59:29-35.
55. Spitz IM. Clinical utility of progesterone receptor modulators and their effect on the endometrium. *Curr Opin Obstet Gynecol* 2009; 21:318.
56. Steinauer J, Pritts EA, Jackson R, Jacoby AF. Systematic review of mifepristone for the treatment of uterine leiomyomata. *Obstet Gynecol* 2004; 103:1331.
57. Stewart EA, Nicholson WK, Bradley L, Borah BJ. The burden of uterine fibroids for African-American women: results of a national survey. *J Womens Health (Larchmt)* 2013; 22:807

58. Stewart EA. Uterine fibroids. *Lancet* 2001;357(9252):293-298
59. Styer AK, Jin S, Liu D, Wang B, Polotsky AJ, Christianson MS, Vitek W, Engmann L, Hansen K, Wild R, Legro RS, Coutifaris C, Alvero R, Robinson RD, Casson P, Christman GM, Christy A, Diamond MP, Eisenberg E, Zhang H, Santoro N; National Institute of Child Health and Human Development Reproductive Medicine Network. Association of uterine fibroids and pregnancy outcomes after ovarian stimulation-intrauterine insemination for unexplained infertility. *Fertil Steril*. 2017 Mar;107(3):756-762.e3.
60. Surrey ES. Impact of intramural leiomyomata on in-vitro fertilisation embryo transfer cycle outcome. 2003; *Curr Opin Obstet Gynecol* 15,239-242.
61. Varghese BV, Koohestani F, McWilliams M, et al. Loss of the repressor REST in uterine fibroids promotes aberrant G protein-coupled receptor 10 expression and activates mammalian target of rapamycin pathway. *Proc Natl Acad Sci U S A* 2013;110(6): 2187-2192
62. Vedantham S, Sterling KM, Goodwin SC, et al. I. Uterine fibroid embolization: preprocedure assessment. *Tech Vasc Interv Radiol* 2002; 5:2.
63. Venkatachalam S, Bagratee JS, Moodley J. Medical management of uterine fibroids with medroxyprogesterone acetate (Depo Provera): a pilot study. *J Obstet Gynaecol* 2004; 24:798
64. Vercellini P, Zaina B, Yaylayan L, Pisacreta A, De Giorgi O, Crosignani PG. Hysteroscopic myomectomy: long-term effects on menstrual pattern and fertility. *Obstet Gynecol*. 1999;94:341-347.
65. Vikhlyaeva EM, Khodzhaeva ZS: Familial predisposition to uterine leiomyomas. *Int J Gynecol Obstet* 51: 127, 1995
66. Vilos GA, Allaire C, Laberge PY, Leyland N; SPECIAL CONTRIBUTORS. The management of uterine leiomyomas. *J Obstet Gynaecol Can*. 2015 Feb;37(2):157-178.
67. Wegienka G, Baird DD, Hertz-Picciotto I, et al. Self-reported heavy bleeding associated with uterine leiomyomata. *Obstet Gynecol* 2003; 101:431.

This image shows a single sheet of white paper with horizontal blue ruling lines. The lines are evenly spaced and run across the width of the page. There are no margins, text, or other markings on the paper.





# Part - 3

## International Guidelines

Table A: SOGC CLINICAL PRACTICE GUIDELINE

Summary statements

Recommendations

Article



In the infertile population, cumulative pregnancy rates by the laparoscopic and the minilaparotomy approaches are similar, but the **laparoscopic approach** is associated with a quicker recovery, less postoperative pain, and less febrile morbidity. (II-2)

Subserosal fibroids do not appear to have an impact on fertility; the **effect of intramural fibroids remains unclear**. If intramural fibroids do have an impact on fertility, it appears to be small and to be even less significant when the endometrium is not involved. (II-3)

There is **little evidence** on the use of Foley catheters, estrogen, or intrauterine devices for the prevention of intrauterine adhesions following hysteroscopic myomectomy. (II-3)

Because current medical therapy for fibroids is associated with suppression of ovulation, reduction of estrogen production, or disruption of the target action of estrogen or progesterone at the receptor level, and it has the potential to interfere in endometrial development and implantation, there is **no role for medical therapy as a stand-alone treatment for fibroids in the infertile population**. (III)

- In women with otherwise unexplained infertility, submucosal fibroids should be removed in order to improve conception and pregnancy rates. (II-2A)
- If fibroids are removed abdominally, efforts should be made to use an anterior uterine incision to minimize the formation of postoperative adhesions. (II-2A)
- Women, fertile or infertile, seeking future pregnancy should not generally be offered uterine artery embolization as a treatment option for uterine fibroids (II-3E)
- In women with infertility, an effort should be made to adequately evaluate and classify fibroids, particularly those impinging on the endometrial cavity, using transvaginal ultrasound, hysteroscopy, hysterosonography, or magnetic resonance imaging (III-A)
- Widespread use of the laparoscopic approach to myomectomy may be limited by the technical difficulty of this procedure. Patient selection should be individualized based on the number, size, and location of uterine fibroids and the skill of the surgeon. (III-A)

Key to evidence statements and grading of recommendations, using the SOGC "Best Case" for Practice Guide 200

Quality of evidence statement	Grading of recommendation
1. Evidence statement that all study subjects had the condition	1. This is a good statement because the study population also had the condition
2. Evidence from well designed studies that all study subjects had the condition	2. This is a good statement because the study population also had the condition
3. Evidence from well designed studies that all study subjects had the condition	3. This is a good statement because the study population also had the condition
4. Evidence from well designed studies that all study subjects had the condition	4. This is a good statement because the study population also had the condition
5. Evidence from well designed studies that all study subjects had the condition	5. This is a good statement because the study population also had the condition
6. Evidence from well designed studies that all study subjects had the condition	6. This is a good statement because the study population also had the condition
7. Evidence from well designed studies that all study subjects had the condition	7. This is a good statement because the study population also had the condition
8. Evidence from well designed studies that all study subjects had the condition	8. This is a good statement because the study population also had the condition
9. Evidence from well designed studies that all study subjects had the condition	9. This is a good statement because the study population also had the condition
10. Evidence from well designed studies that all study subjects had the condition	10. This is a good statement because the study population also had the condition

The SOGC Clinical Practice Guidelines are developed by the SOGC Clinical Practice Guidelines Committee. The SOGC Clinical Practice Guidelines are developed by the SOGC Clinical Practice Guidelines Committee. The SOGC Clinical Practice Guidelines are developed by the SOGC Clinical Practice Guidelines Committee.



Article	Summary statements	Recommendations
<p><b>Article</b></p> <p><b>Summary statements</b></p> <p>Preoperative assessment of submucosal fibroids is essential to the decision on the best approach for treatment. (I)</p> <p>There are <b>lower pregnancy rates</b>, higher miscarriage rates, and more adverse pregnancy outcomes following <b>uterine artery embolization</b> than after myomectomy. (II-3)</p> <p>Studies also suggest that uterine artery embolization is associated with loss of ovarian reserve, especially in older patients. (III)</p>		<ul style="list-style-type: none"> <li>• Preoperative assessment of submucosal fibroids should include, in addition to an assessment of fibroid size and location within the uterine cavity, evaluation of the degree of invasion of the cavity and thickness of residual myometrium to the serosa. A combination of hysteroscopy and transvaginal ultrasound or hysterosonography is the modalities of choice. (III-B)</li> <li>• Submucosal fibroids are managed hysteroscopically. The fibroid size should be &lt; 5 cm, although larger fibroids have been managed hysteroscopically, but repeat procedures are often necessary. (III-B)</li> <li>• There is fair evidence to recommend against myomectomy in women with intramural fibroids (hysteroscopically confirmed intact endometrium) and otherwise unexplained infertility, regardless of their size. (II-2D) If the patient has no other options, the benefits of myomectomy should be weighed against the risks, and management of intramural fibroids should be individualized. (III-C)</li> <li>• A hysterosalpingogram is not an appropriate exam to evaluate and classify fibroids. (III-D)</li> <li>• Removal of subserosal fibroids is not recommended. (III-D)</li> </ul>

50000 CLINICAL PRACTICE GUIDELINE

Issue 17, March 2013

**The Management of Uterine Fibroids in Women With Otherwise Unexplained Infertility**

**Abstract**

Uterine fibroids are a common cause of infertility. The purpose of this guideline is to provide evidence-based recommendations for the management of uterine fibroids in women with otherwise unexplained infertility. The guideline is based on a systematic review of the literature and a panel of experts in the field.

**Key Words:** Uterine fibroids, infertility, hysteroscopy, myomectomy, uterine artery embolization, hysterosalpingogram.

**Objectives:** The objectives of this guideline are to provide evidence-based recommendations for the management of uterine fibroids in women with otherwise unexplained infertility.

**Recommendations:** The panel recommends that preoperative assessment of submucosal fibroids should include, in addition to an assessment of fibroid size and location within the uterine cavity, evaluation of the degree of invasion of the cavity and thickness of residual myometrium to the serosa. A combination of hysteroscopy and transvaginal ultrasound or hysterosonography is the modalities of choice. (III-B)

The panel recommends that submucosal fibroids are managed hysteroscopically. The fibroid size should be < 5 cm, although larger fibroids have been managed hysteroscopically, but repeat procedures are often necessary. (III-B)

The panel recommends that there is fair evidence to recommend against myomectomy in women with intramural fibroids (hysteroscopically confirmed intact endometrium) and otherwise unexplained infertility, regardless of their size. (II-2D) If the patient has no other options, the benefits of myomectomy should be weighed against the risks, and management of intramural fibroids should be individualized. (III-C)

The panel recommends that a hysterosalpingogram is not an appropriate exam to evaluate and classify fibroids. (III-D)

The panel recommends that removal of subserosal fibroids is not recommended. (III-D)

1. There is fair evidence to recommend against myomectomy in women with intramural fibroids (hysteroscopically confirmed intact endometrium) and otherwise unexplained infertility, regardless of their size. (II-2D) If the patient has no other options, the benefits of myomectomy should be weighed against the risks, and management of intramural fibroids should be individualized. (III-C)

2. There is fair evidence to recommend against myomectomy in women with intramural fibroids (hysteroscopically confirmed intact endometrium) and otherwise unexplained infertility, regardless of their size. (II-2D) If the patient has no other options, the benefits of myomectomy should be weighed against the risks, and management of intramural fibroids should be individualized. (III-C)

3. There is fair evidence to recommend against myomectomy in women with intramural fibroids (hysteroscopically confirmed intact endometrium) and otherwise unexplained infertility, regardless of their size. (II-2D) If the patient has no other options, the benefits of myomectomy should be weighed against the risks, and management of intramural fibroids should be individualized. (III-C)

4. There is fair evidence to recommend against myomectomy in women with intramural fibroids (hysteroscopically confirmed intact endometrium) and otherwise unexplained infertility, regardless of their size. (II-2D) If the patient has no other options, the benefits of myomectomy should be weighed against the risks, and management of intramural fibroids should be individualized. (III-C)

5. There is fair evidence to recommend against myomectomy in women with intramural fibroids (hysteroscopically confirmed intact endometrium) and otherwise unexplained infertility, regardless of their size. (II-2D) If the patient has no other options, the benefits of myomectomy should be weighed against the risks, and management of intramural fibroids should be individualized. (III-C)

6. There is fair evidence to recommend against myomectomy in women with intramural fibroids (hysteroscopically confirmed intact endometrium) and otherwise unexplained infertility, regardless of their size. (II-2D) If the patient has no other options, the benefits of myomectomy should be weighed against the risks, and management of intramural fibroids should be individualized. (III-C)

7. There is fair evidence to recommend against myomectomy in women with intramural fibroids (hysteroscopically confirmed intact endometrium) and otherwise unexplained infertility, regardless of their size. (II-2D) If the patient has no other options, the benefits of myomectomy should be weighed against the risks, and management of intramural fibroids should be individualized. (III-C)


8. There is fair evidence to recommend against myomectomy in women with intramural fibroids (hysteroscopically confirmed intact endometrium) and otherwise unexplained infertility, regardless of their size. (II-2D) If the patient has no other options, the benefits of myomectomy should be weighed against the risks, and management of intramural fibroids should be individualized. (III-C)


9. There is fair evidence to recommend against myomectomy in women with intramural fibroids (hysteroscopically confirmed intact endometrium) and otherwise unexplained infertility, regardless of their size. (II-2D) If the patient has no other options, the benefits of myomectomy should be weighed against the risks, and management of intramural fibroids should be individualized. (III-C)

10. There is fair evidence to recommend against myomectomy in women with intramural fibroids (hysteroscopically confirmed intact endometrium) and otherwise unexplained infertility, regardless of their size. (II-2D) If the patient has no other options, the benefits of myomectomy should be weighed against the risks, and management of intramural fibroids should be individualized. (III-C)




**Table B : AAGL Practice Report :  
Practice Guidelines for the Diagnosis and Management of Submucous Leiomyomas**

Article	Level A	Level B	Level C
	<p>The Following Recommendations and Conclusions are Based on Good and Consistent Scientific Evidence</p> <p>Submucous leiomyomas contribute to infertility, and although their removal improves pregnancy rates, the fertility rate remains lower than is the case for women with normal uteri.</p> <p>Hysteroscopy, infusion sono-hystero-graphy (saline solution, gel) and MRI are all highly sensitive and specific for the diagnosis of submucous leiomyomas.</p> <p>Hysterosalpingography is less sensitive for diagnosing submucous myomas than hysteroscopy, infusion sono-hystero-graphy, and MRI, and is much less specific.</p> <p>Transvaginal ultrasound is less sensitive and less specific for diagnosing submucous myomas than hysteroscopy and infusion sonohystero-graphy.</p> <p>Endometrial ablation can be an effective therapy for selected women with type 2 leiomyomas and HMB who do not wish to become pregnant in the future.</p>	<p>The Following Recommendations and Conclusions are Based on Limited or Inconsistent Scientific Evidence</p> <p>Submucous myomas increase the risk of recurrent early pregnancy loss.</p> <p>The LNG-IUS appears to reduce the incidence of submucous leiomyomas.</p> <p>If fertility enhancement is not a goal, women with asymptomatic submucous myomas can be watched expectantly.</p> <p>The impact of leiomyoma ablation techniques on submucous leiomyomas and the overlying and nearby endometrium has not been established.</p> <p>The role for GnRHa administered for the purpose of reducing operating time, the amount of systemic absorption of distention media, and the risk of incomplete resection of submucous myomas has not been established.</p> <p>For women desiring future fertility, or who are currently infertile, an abdominal approach to submucous myomectomy should be considered when there are 3 or more submucous myomas or in other circumstances where hysteroscopic myomectomy might be anticipated to damage a large portion of the</p>	<p>The Following Recommendations and Conclusions are Based Primarily on Consensus and Expert Opinion</p> <p>The direct source of abnormal uterine bleeding in women with submucous myomas is usually the endometrium itself, a circumstance that allows for the selection of medical therapies aimed at the endometrium or for endometrial destruction, provided fertility is not an issue.</p> <p>With currently available evidence, embolic and ablative therapies are not appropriate for women with submucous myomas who have current infertility or who wish to conceive in the future. These techniques include UAE and occlusion, as well as leiomyoma ablation with radiofrequency electricity, cryotherapy, and MRg-FUS.</p> <p>When planning the appropriate surgical approach, the surgeon should personally evaluate the images from any uterine imaging studies.</p> <p>If hysteroscopic myomectomy is to be performed with a monopolar or bipolar resectoscope or any other surgical device, the surgeon should be familiar both with the device and the related fundamentals of electrosurgery or other energy source. When performing radiofrequency electrosurgical procedures with</p>

Article	Level A	Level B	Level C
 <p><b>ASRM Practice Report: Practice Guidelines for the Diagnosis and Management of Submucosal Leiomyomas</b></p> <p>2016. American Society for Reproductive Medicine</p>	<p>Cervical preparation techniques can reduce the requirement for dilation, and, likely, the incidence of uterine trauma associated with hysteroscopic surgery, including hysteroscopic myomectomy for submucous myomas. This can be accomplished before surgery with laminaria or prostaglandins or during surgery with intracervical injection of a low dose of dilute vasopressin solution.</p>	<p>endometrial surface.</p> <p>Hysteroscopic myomectomy with the removal of the entire myoma is effective for the relief of HMB.</p> <p>If hysteroscopic myomectomy is performed for AUB, and future fertility is not an issue, concomitant endometrial ablation may reduce the risk of subsequent uterine surgery.</p> <p>The risk of monopolar current diversion resulting in lower genital tract burns may be reduced by maintaining contact of the external sheath with the cervix, avoiding activation of the electrosurgical unit when the electrode is not in contact with tissue, ensuring the sustained integrity of the electrode insulation, and minimizing the use of high-voltage ("coagulation") current when performing hysteroscopic submucous myomectomy.</p> <p>Postmyomectomy intrauterine synechiae are more common after multiple submucous myomectomies. In such circumstances, and when fertility is an issue, secondlook hysteroscopy and appropriate adhesiolysis should be considered.</p>	<p>monopolar instruments, it is mandatory to use electrolyte-free fluid distension media such as 5% mannitol, 5% glycine, or 3% sorbitol. Provided the use of careful fluid monitoring and adherence to protocols designed to terminate procedures if unacceptable thresholds are met, there is no currently available evidence to suggest that one hysteroscopic fluid distension medium is safer than the other. However, 5% mannitol is isosmolar and is an osmotic diuretic, features that make it theoretically safer than other electrolyte-free options for uterine distention.</p> <p>Provided adequate training, available equipment, and appropriate analgesia or anesthesia, small submucous myomas can be removed in the office setting.</p> <p>There may be a role for concomitant laparoscopy or ultrasound when hysteroscopic myomectomy is performed on deep type 2 submucous myomas.</p> <p>Second-look hysteroscopy may be effective for postoperative intrauterine adhesions and thereby could reduce the long-term risk of adhesion formation.</p>

**Table C : Removal of Myoma in asymptomatic patients to improve fertility and/ or reduce miscarriage rates : A Guideline by ASRM**

Article	Summary Statements	Recommendations
<p> <b>Removal of myomas in asymptomatic patients to improve fertility and/or reduce miscarriage rate: a guideline</b></p> <p><small>Practice Committee of the American Society for Reproductive Medicine This document is only for reproductive medicine. Intended for: All.</small></p> <p><small>The purpose of this guideline is to assist in the selection of patients to undergo the removal of myomas (uterine fibroids) and to provide a framework for the management of these patients. The guideline is based on a systematic review of the literature and is intended to be used in conjunction with the clinical judgment of the physician. The guideline is not intended to replace the clinical judgment of the physician. The guideline is not intended to be used in conjunction with the clinical judgment of the physician. The guideline is not intended to be used in conjunction with the clinical judgment of the physician.</small></p> <p><small>Copyright © 2017 by American Society for Reproductive Medicine Reproduction of this document is permitted for personal or internal use only. For all other uses, permission must be obtained from the American Society for Reproductive Medicine.</small></p>	<p>Heterogeneous study designs, inconsistent nomenclature, continuous nature of leiomyomas size and location, and insufficient patient recruitment significantly limit the interpretation of results from existing studies that evaluate the impact of fibroids on the likelihood of achieving pregnancy and maintenance of pregnancy.</p>	<p>In <b>asymptomatic women with cavity-distorting myomas</b> (intramural with submucosal component or submucosal), <b>myomectomy</b> (open or laparoscopic or hysteroscopic) <b>may be considered</b> to improve pregnancy rates.</p>
	<p><b>Grade B</b></p> <p>There is fair evidence that myomectomy does not impair reproductive outcomes (clinical pregnancy rates, live birth rates) following ART.</p> <p>There is fair evidence that hysteroscopic myomectomy for submucosal fibroids improve clinical pregnancy rates.</p>	<p>Myomectomy is generally not advised to improve pregnancy outcomes in asymptomatic infertile women with cavity-distorting myomas. However, myomectomy may be reasonable in some circumstances, including but not limited to severe distortion of pelvic architecture complicating access to the ovaries for oocyte retrieval.</p> <p>The strength of the recommendations was evaluated as follows: Grade A : There is good evidence to support the recommendations, either for or against. Grade B : there is fair evidence to support the recommendations, either for or against. Grade C: There is insufficient evidence to support the recommendations, either for or against</p>
	<p><b>Grade C</b></p> <p>There is insufficient evidence to conclude that myomas reduce the likelihood of achieving pregnancy with or without fertility treatment.</p> <p>There is insufficient evidence to determine that a specific myoma size, number, or location (excluding submucosal myomas or intramural myomas impacting the endometrial cavity contour) is associated with a reduced likelihood of achieving pregnancy or an increased risk of early pregnancy loss.</p> <p>There is insufficient evidence that removal of Subserosal fibroids improves fertility.</p> <p>There is insufficient evidence that myomectomy (laparoscopic or open) reduces miscarriage rates.</p> <p>There is insufficient evidence to conclude that hysteroscopic myomectomy reduces the likelihood of early pregnancy loss in women with infertility and a submucous fibroid.</p>	



**ZyFSH**  **75/150 IU**  
Recombinant-Human Follicle Stimulating Hormone

**ZyhMG**  **75**  
**Menotrophin** **150**

**Ovucet**  
Cetorelix Acetate 0.25mg for injection

**Letisha**  
Letrozole 2.5 mg Tablets

**ZyStim**  
Filgrastim 300 µg/ml single dose pre-filled syringe

Contact :  
Prof pankaj Talwar  
9810690063,  
pankaj\_1310@yahoo.co.in

**Zy****+****dus**  
dedicated  
to *life*

**Gynova**  
MAKES DREAM COME TRUE