



Indian FERTILITY Society

SONO-NAVIGATOR SERIES

ROLE OF ULTRASOUND IN DIAGNOSING ADENOMYOSIS

INTRODUCTION

Adenomyosis was first described by Rokitansky in 1860 as “**cystosarcoma adenoides uterinum**”.

It is a common condition, characterized by migration of endometrial glands and stroma from the stratum basale into the myometrium. This often occurs in association with reactive hyperplasia of the surrounding myometrial smooth muscle. It is most prevalent among middle-aged multiparous women and much less common in nulliparous or postmenopausal patients. Symptoms vary from being completely asymptomatic to uterine tenderness, dysmenorrhea, menorrhagia, infertility and uterine enlargement.

ROLE OF IMAGING IN DIAGNOSIS

Transvaginal Sonography	MRI	3D Ultrasound
First line imaging. Reported sensitivity and specificity of transvaginal sonography range from 53% to 89% and 67% to 98%, respectively, and overall accuracy is reported to range from 68% to 86. (fig. 1) Probe tenderness observed	Better specificity and accuracy, particularly in women with associated disorders like leiomyoma. MRI has a sensitivity of 78-88% and a specificity of 67-93%. (fig. 2)	May be superior for assessment of junctional zone . Disruption and infiltration of the subendometrial halo by the hyperechoic endometrium and the thickness of subendometrial halo can be measured at sonography and can be helpful in diagnosing adenomyosis. (fig. 3)

RADIOGRAPHIC FEATURES

Three forms have been described:

- ▶ Diffuse adenomyosis: most common and generalised.
- ▶ Focal adenomyosis and adenomyoma: In some cases, adenomyosis may be localised, forming a mass.
- ▶ Cystic adenomyosis and adenomyotic cyst: A rare variant, believed to be the result of repeated focal haemorrhages resulting in cystic spaces filled with altered blood products.

TYPICAL ULTRASOUND FEATURES

1. **Uterine enlargement—Globular uterine enlargement** that is generally up to 12 cm in uterine length ,not explained by the presence of leiomyomata is a characteristic finding.
2. **Cystic anechoic spaces or lakes in the myometrium (specific sign)** — Variable in size and can occur throughout the myometrium- reflect glands filled with fluid .On occasions,these may represent small arcuate veins rather than adenomyomas. The application of color Doppler imaging at low velocity scales may help to differentiate.
3. **Uterine wall thickening** - The uterine wall thickening typically of fundal and posterior wall, can show anteroposterior asymmetry. (fig.4)
4. **Subendometrial echogenic linear striations (specific sign) - Venetian bands or rain shower appearance.** Invasion of the endometrial glands into the subendometrial tissue induces a hyperplastic reaction, which appears as echogenic linear striations fanning out from the endometrial layer. (fig 4)
5. **Heterogeneous echo texture** - There is a lack of homogeneity within the myometrium with evidence of architectural disturbance .
6. **Obscure endometrial/myometrial border** - Invasion of the myometrium by the glands obscures the normally distinct endometrial/myometrial border.
7. **Thickening of the transition zone** - This zone is a layer that appears as a hypoechoic halo surrounding the endometrial layer. A **thickness of 12 mm or greater** has been shown to be associated with adenomyosis.
8. **Diffuse Hypervascularity** - Color and power Doppler sonography often demonstrate diffuse hypervascularity without large feeding vessels. (fig 5)
9. **Question Mark sign**, a novel sign - Seen when the uterine corpus is flexed backward, the fundus of the uterus is facing the posterior pelvic compartment and the cervix is directed anteriorly towards the urinary bladder. This alone has a high specificity (93%).(fig. 6)

DIFFERENTIAL DIAGNOSIS

S.No.	For Diffuse Adenomyosis
1.	Normal uterus
2.	Diffuse uterine leiomyomatosis
3.	Myometrial contraction: transient
4.	Malignancy - endometrial carcinoma - endometrial stromal sarcoma (ESS)

DIFFERENTIAL DIAGNOSIS

S.No.	For Focal Adenomyoma
1.	<p>Uterine fibroma (leiomyoma)</p> <ul style="list-style-type: none"> -Better defined than adenomyoma -May have pseudocapsule of compressed adjacent myometrial tissue -On colour Doppler: tend to displace vessels, demonstrating circumferential peripheral flow
2.	<p>Uterine contractions</p> <ul style="list-style-type: none"> -transient in nature
3.	<p>Vascular malformations</p> <ul style="list-style-type: none"> -Does not disrupt the endometrial-myometrial interface -On colour Doppler: demonstrates turbulent high - velocity flow
4.	<p>Malignancy</p> <ul style="list-style-type: none"> - endometrial carcinoma - endometrial stromal sarcoma (ESS) - uterine tumour (e.g. uterine leiomyosarcoma) - myometrial metastases

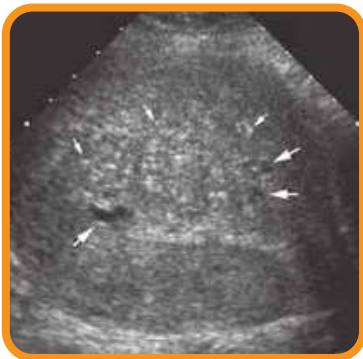


Fig 1. Enlarged uterus with typical features of adenomyosis. Multiple bright echogenic foci are seen throughout the myometrium (small arrows) in addition to numerous subendometrial myometrial anechoic cysts (large arrows).

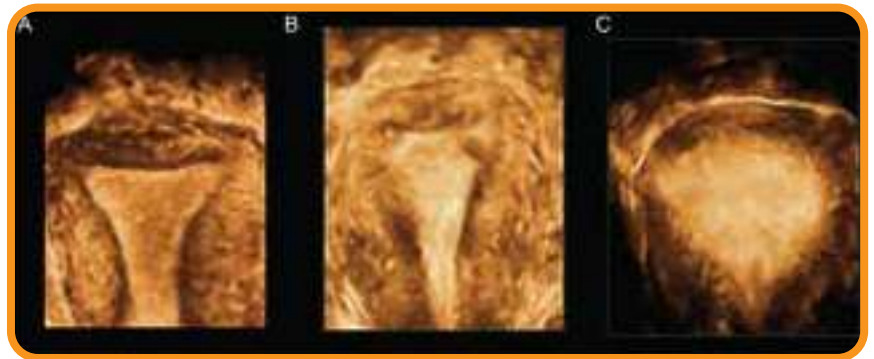


Fig 3. A. Normal Junctional zone; B& C- irregular transitional zone in adenomyosis

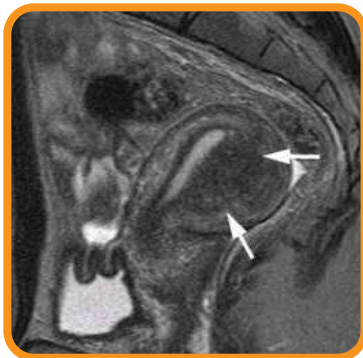

Fig 2. Mri image of adenomyoma

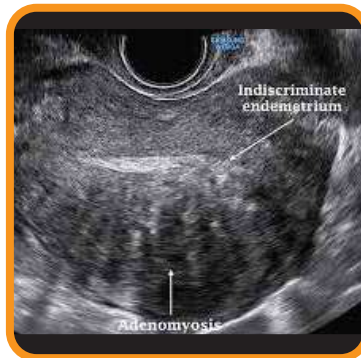

Fig 4: Globular uterus showing thickened posterior wall, indiscriminate endometrium, heterogenous architecture and venetian bands.

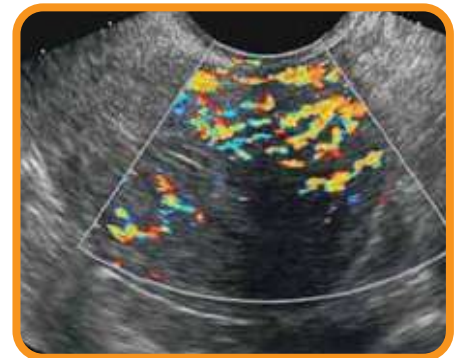


fig. 5: Diffuse vascularity within adenomyoma

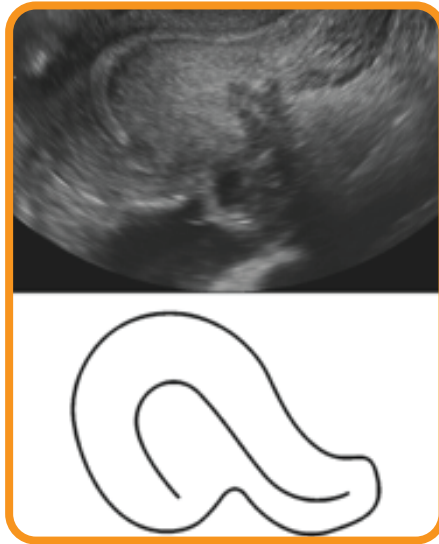

fig 6: Question mark sign in adenomyosis

References

1. Shwayder J, Sakhel K: Imaging for uterine myomas and adenomyosis. J Minim Invasive Gynecol 21:362–366, 2014.
2. Luciano DE, Exacoustos C, Albrecht L, et al: Three-dimensional ultrasound in diagnosis of adenomyosis: histologic correlation with ultrasound targeted biopsies of the uterus. J Minim Invasive Gynecol 20:803–810, 2013.
3. Takeuchi M, Matsuzaki K: Adenomyosis: usual and unusual imaging manifestations, pitfalls and problem-solving MR imaging techniques. Radiographics 31(1):99–115, 2011.

Book References

1. Callen.P.W. (2008).Ultrasound in obstetrics and gynaecology.Philadelphia:Saunders. Elsevier.
2. Abuhamad A.(2014). Ultrasound in obstetrics and gynaecology: A practical approach.

Dr M Gouri Devi
President

Dr Pankaj Talwar
Secretary General

Contributor
Dr Gunjan Bhatnagar
Fellow IFS

Dr Ashok Khurana
SIG Convenor
Reproductive Ultrasound

Dr Ritu Khanna
SIG Co-convenor
Reproductive Ultrasound

IFS Secretariat

302, 3rd Floor, Kailash Building
Kasturba Gandhi Marg, C.P, New Delhi-110001

Contact No. 9899308083 Email Address - indianfertilitysocietydelhi@gmail.com Web - indianfertilitysociety.org

WHY TO JOIN IFS

IFS is a Multi-disciplinary Society that values the input and participation of professionals in the scope of Reproductive Medicine.



Dr. M Gouri Devi
President



Dr. Pankaj Talwar
Secretary General

IFS MEMBERSHIP Benefits At A Glance

Pan India Society

Collaboration with ESHRE & IFFS

2414 Members & 26 Chapters

National Conference Fertilvision every year with reduced registration fees

Special Interest Group (13) for IFS Members to show cast their talent

Research Wing of IFS has its own ethical committee for Research Project approval

Publication Wing - Fertility Science & Research Journal

IFS Fellowship Program in Clinical ART & Embryology in collaboration with Amity University


ESHRE Certified Embryologist Examination in India, conducted by IFS every year

IFS Outreach activities all over India

IFS Master Courses

Free access to IFS E-Pathshala contents and Official Journal

IFS E-Pathshala - IFS Conversation, Nexus, ARTtext, Fertility News, CATALYST



indianfertilitysocietyifs



ifsdelhi



indianfertilitysociety/



IFS SECRETARIAT

302, 3rd Floor, Kailash Building,
26, Kasturba Gandhi Marg, CP,
New Delhi-110001



+91 9667742015



+91 9899308083



+91 11 40018184



indianfertilitysocietydelhi@gmail.com



www.indianfertilitysociety.org



INDIAN FERTILITY SOCIETY

IFS is a Multi-Disciplinary Society that values the input and participation of professionals in the scope of Reproductive Medicine.

2350+ Members

25 State Chapters

How To Join IFS

IFS Life Membership Fees

Clinicians:-

Rs. 5932/- + (18% GST -1068) = Rs.7000/-

Non Clinicians:-

Rs. 4237/- + (18% GST -763) = Rs. 5000/-

Online Procedure

It is the easiest way to Register yourself as the lifetime member of our family. while following the procedure, fill the online membership form and pay the membership fee.

Your registration number would be generated and you will get your membership certificate and also access to member portal on our website where you can manage your profile and get all important notification.

Offline Procedure

You can pay by cash or card at the registration counter provided.

or

you can easily download our offline membership form or use the offline form attached with this document, fill all required information attach the membership fee DD or Cheque and send on our secretariat address.

Account Details:

Account No: 50562010067180 | IFSC Code: ORBC0100179

Bank Name: Oriental Bank of Commerce

Branch: Connaught Place, New Delhi-110001

Dr. M. Gouri Devi

President

Dr. Pankaj Talwar

Secretary General

IFS Secretariat

Flat No. 302, 3rd Floor,
Kailash Building,
26, Kasturba Gandhi Marg,
C.P. New Delhi – 110001

+91 9667742015

+91-9899308083

91-1140018184

indianfertilitysocietydelhi@gmail.com

info@indianfertilitysociety.org

indianfertilitysocietyifs

ifsdelhi

indianfertilitysociety



INDIAN FERTILITY SOCIETY

Offline Registration Form

Download the form and send to the secretariat with recent pic and cheque/draft

Name	<input type="text"/>	Qualification	<input type="text"/>
Date of Birth	<input type="text"/>	Designation	<input type="text"/>
Workplace Phone No	<input type="text"/>	Residence Phone No	<input type="text"/>
Mobile	<input type="text"/>	E-mail	<input type="text"/>

Workplace Address

State

Residence Address

IFS Chapter

Address to be used for correspondence

Workplace

Residence

Account Details:

Account No: 50562010067180 | IFSC Code: ORBC0100179
 Bank Name: Oriental Bank of Commerce
 Branch: Connaught Place, New Delhi-110001

Payment Details :

Amount :
 Cash / Cheque / Demand Draft No. : Dated :
 Bank : :
 Signature : : Name : Date :

IFS Life Membership Fees

Clinicians:-
 Rs. 5932/- + (18% GST -1068) = Rs.7000/-

Non Clinicians:-
 Rs. 4237/- + (18% GST -763) = Rs. 5000/-

* Please make Cheque / Draft in favour of "INDIAN FERTILITY SOCIETY" payable at New Delhi.

*Please attaché two recent passport size photographs.

Who can apply for IFS Membership : All Professionals with postgraduate qualification such as Obstetricians & Gynaecologists, Clinical embryologists, andrologists, ultrasonologists, counsellors, geneticists and other involved in the care of infertility patients.

IFS Secretariat
 Flat No. 302, 3rd Floor,
 Kailash Building,
 26, Kasturba Gandhi Marg,

+91 9667742015
 +91-9899308083
 91-1140018184

indianfertilitysocietydelhi@gmail.com
 info@indianfertilitysociety.org
 indianfertilitysocietyifs
 ifcdelhi